UNIVERSIDADE PAULISTA
PROGRAMA DE PÓS-GRADUAÇÃO EM ODONTOLOGIA

AS MODIFICAÇÕES MACRO E MICROGEOMÉTRICAS DOS IMPLANTES DENTÁRIOS PODEM INFLUENCIAR O REPARO ÓSSEO PERI-IMPLANTAR EM FUMANTES? UM ENSAIO CLÍNICO RANDOMIZADO

Tese apresentada ao Programa de Pós-Graduação em Odontologia da Universidade Paulista – UNIP, para a obtenção do título de Doutor em Odontologia.

ANDRE LUIS SEFERIAN OBICE

SÃO PAULO
2022

UNIVERSIDADE PAULISTA

PROGRAMA DE PÓS-GRADUAÇÃO EM ODONTOLOGIA

AS MODIFICAÇÕES MACRO E MICROGEOMÉTRICAS DOS IMPLANTES DENTÁRIOS PODEM INFLUENCIAR O REPARO ÓSSEO PERI-IMPLANTAR EM FUMANTES? UM ENSAIO CLÍNICO RANDOMIZADO

Tese apresentada ao Programa de Pós-Graduação em Odontologia da Universidade Paulista – UNIP, para a obtenção do título de Doutor em Odontologia.

Área de Concentração: Clínica Odontológica (Subárea: Implantodontia)

Orientador: Prof. Dr. Fabiano Ribeiro Cirano.

ANDRE LUIS SEFERIAN OBICE

SÃO PAULO

2022

Óbice, André Luis Seferian.
As modificações macro e microgeométricas dos implantes dentários podem influenciar o reparo ósseo peri-implantar em fumantes? Um ensaio clínico randomizado / André Luis Seferian Óbice. - 2022.
46 f. : il. color.

Teses de Doutorado apresentada ao Programa de Pós-Graduação em Odontologia, São Paulo, 2022.

Área de concentração: Implantodontia.
Orientador: Prof. Dr. Fabiano Ribeiro Cirano.

1. Implantes dentários. 2. Macrogeometria. 3. Tratamento de superfície. 4. Marcadores ósseos. I. Cirano, Fabiano Ribeiro (orientador). II. Título.

Ficha elaborada pelo Bibliotecário Rodney Eloy CRB8-6450

ANDRE LUIS SEFERIAN OBICE

AS MODIFICAÇÕES MACRO E MICROGEOMÉTRICAS DOS IMPLANTES DENTÁRIOS PODEM INFLUENCIAR O REPARO ÓSSEO PERI-IMPLANTAR EM FUMANTES? UM ENSAIO CLÍNICO RANDOMIZADO

Dissertação de Doutorado apresentada ao Programa de Pós-Graduação em Odontologia da Universidade Paulista – UNIP, para a obtenção do título de Mestre em Odontologia.

Aprovado em:

BANCA EXAMINADORA

_____ ___/___/201__.
Prof. Dr. Sérgio Luis Scombatti de Souza
FORP - USP

_____ ___/___/201__.
Prof. Dr. Jamil Awad Shibli
UNG

_____ ___/___/201__.
Prof. Dra. Mabelle de Freitas Monteiro
UNIP

_____ ___/___/201__.
Prof. Dr. Marcio Zaffalon Casati
UNIP

_____ ___/___/201__.
Prof. Dr. Fabiano Ribeiro Cirano
UNIP

AGRADECIMENTOS

A Deus em primeiro lugar, por permitir essa grande oportunidade e ter me dado força para seguir em frente, sem Ele é impossível seguir em frente.

Aos meus pais José Antônio Vital Óbice e Daisy Seferian Óbice, por me orientarem e apoiarem assiduamente nas escolhas profissionais e pelo incansável esforço para me proporcionar minha formação profissional e pessoal.

A minha esposa, conselheira e companheira Karina Seferian, que sempre me apoiou, e mesmo nos momentos que foram muito difíceis estava como coluna em minha vida.

Agradeço à equipe de implantodontia da APOIO, por fazerem parte da minha história acadêmica e evolução profissional.

Ao Prof. Dr. Fabiano Ribeiro Cirano, orientador deste trabalho, por ter me aceitado como orientado, tendo em mim depositado grande confiança durante todo o decorrer deste trabalho.

À toda equipe de Periodontia da UNIP/SP: Dra. Mônica Grazieli, Dr. Márcio Zaffalon Casatti, Profa. Dra. Suzana Pimentel, Dra. Mabelle de Freitas Monteiro pelo trabalho conjunto e pelo apoio durante todo o percurso deste trabalho.

RESUMO

Este estudo clínico de boca dividida, duplo cego e randomizado teve como objetivo avaliar o impacto de modificações na macrogeometria e nanotopografia de implantes sobre o reparo ósseo peri-implantar em fumantes. Trinta e dois pacientes (>10 cigarros/dia), com a necessidade de um único implante maxilar ou mandibular bilateralmente, receberam dois implantes aleatoriamente atribuídos em dois grupos: DA - Implantes duplo ataque Acido (n=32); HCAN – câmaras de cicatrização e nanosuperfície ativada (n=32). O coeficiente de estabilidade do implante (ISQ) foi avaliado no tempo 0 (baseline) e após 30, 60, 90 e 120 dias da instalação do implante. Níveis de Dickkopf-1 (DKK1), osteoprotegerina (OPG), osteopontina (OPN), fator de crescimento endotelial vascular (VEGF), fator de crescimento epidérmico (EGF), fator de crescimento fibroblástico (FGF), fator de crescimento placentário (PLGF), osteocalcina (OC), proteína morfogenética óssea-9 (BMP-9), fator de necrose tumoral (TNF) alfa e ativador receptor de ligante de fator nuclear-κB (RANKL) foram quantificados no fluido peri-implantar após 07, 15, 30, 90 e 120 dias da instalação do implante. O ISQ foi maior para implantes HCAN em 60 dias em comparação com implantes DA ($p<0,05$). Os níveis de PLGF foram menores para implantes HCAN em 07 dias em comparação com implantes DA ($p<0,05$). Além disso, os implantes HCAN apresentaram níveis mais elevados de OPG em 30 dias e OPN, BMP-9, FGF-1, PLGF e VEGF em 90 dias, quando comparados aos implantes DA ($p<0,04$). Os níveis de EGF foram mais elevados para implantes HCAN em 15, 90 e 120 dias em comparação com implantes DA ($p<0,05$). Os implantes HCAN também apresentaram níveis mais baixos de TNF-α em 07 dias ($p<0,05$) em comparação com os implantes DA ($p<0,05$), mas apresentaram níveis mais elevados de DKK1 em 30 dias, enquanto os implantes DA apresentaram maior nível deste marcador em 90 dias ($p<0,05$). As modificações na macrogeometria e nanotopografia dos implantes modularam positivamente os fatores ósseos e angiogênicos, resultando em maior produção desses marcadores durante a fase inicial da cicatrização óssea peri-implantar e tiveram efeito positivo na estabilidade de implante em fumantes.

Palavras-chave: implantes dentários, tratamento de superfície, osso, marcadores biológicos, matriz de proteínas.

ABSTRACT

This split-mouth, doble-blind, randomized clinical trial aimed at evaluating the impact of different macrogeometries and nanotopographical modifications on peri-implant bone repair in smokers. Thirty-two patients who smoked at least 10 cigarettes/day, with the need of a single maxillary or mandibular implant bilaterally, received two implants randomly assigned in two groups: DA - Dual Acid-Etched implants (n=32); HCAN – healing chambers and activated nanosurface (n=32). Implant stability quotient (ISQ) was evaluated at 07, 30, 60, 90 and 120 days after implant placement. Levels of Dickkopf-1 (DKK1), osteoprotegrin (OPG), ostopontin (OPN), vascular endothelial growth factor (VEGF), epidermal growth factor (EGF), fibroblast growth factor (FGF), placental growth factor (PlGF), osteocalcin (OC), bone morphogenetic protein-9 (BMP-9), tumor necrosis factor (TNF) alpha and receptor activator of nuclear factor-κB ligand (RANKL) were quantified in the peri-implant fluid after 07, 15, 30, 90 and 120 days of implant insertion. The ISQ was higher for HCAN implants at 60 days' time-point compared to DA implants ($p<0.05$). PLGF levels were lower for HCAN implants at 07 days period compared to DA implants ($p<0.05$). Besides, HCAN implants presented higher levels of OPG at 30 days period and OPN, BMP-9, FGF-1, PLGF and VEGF at 90 days period, when compared to DA implants ($p<0.04$). The levels of EGF were higher for HCAN implants at 15, 90 and 120 days-time point comparing with DA implants ($p<0.05$). HCAN implants also showed lower levels of TNF-α at 07 days' time-point ($p<0.05$) in comparison to DA implants ($p<0.05$) but had higher levels of DKK1 at 30-days' time-point in while DA implants presented higher level of this marker at 90 days' time-point ($p<0.05$). Macrogeometry and nanotopographical modifications positively modulated the bone and angiogenic factors resulting in higher production of these markers during early peri-implant bone healing and had positive effect on implant stabilization in smokers.

Keywords: dental implants, surface treatment, bone, biological markers, protein array.

SUMÁRIO

1 INTRODUÇÃO

O tabagismo tem sido considerado como um fator de risco para falha de implantes dentários (Chen, Liu, Xu, Qu, & Lu, 2013; Chrcanovic, Albrektsson, & Wennerberg, 2015; Moraschini, 2016; Strietzel et al., 2007) e para o desenvolvimento da peri-implantite (Heitz-Mayfield, 2008; Renvert & Quirynen, 2015; Pimentel et al., 2018). Além disso, tem sido observada uma maior perda óssea marginal peri-implantar em tabagistas, quando comparados com não fumantes (Qian, Wennerberg, & Albrektsson, 2012), assim observa-se que pessoas que fumam muito podem ter uma maior incidência de falha de implantes (Alsaadi, Quirynen, Komarek, & van Steenberghe, 2007; Twito & Sade, 2014; van Steenberghe, Facobs, Desnyder, Maffei, & Quirynen, 2002). Ademais, ainda nesse sentido, alguns estudos epidemiológicos relataram que o fumo reduz a densidade óssea e aumenta a ocorrência de fratura óssea, levando a um atraso na reparação óssea e alteração do metabolismo ósseo (Vestergaard & Mosekild, 2003, Giorgetti et al., 2010).

Constata-se, nessa perspectiva, que mecanismos fisiopatológicos poderiam ajudar a explicar o impacto negativo do tabagismo nos tecidos peri-implantares, incluindo alterações em fatores ósseos e angiogênicos importantes, tais como o fator nuclear kappa-B (RANK), receptor ativador ligante do fator nuclear kappa-B (RANKL) e osteoprotegerina (OPG) [sistema RANK-RANKL-OPG], proteínas morfogenéticas ósseas (BMPs), fator de crescimento transformador-β (TGF-β) e fosfatase alcalina (ALP) (Ma et al., 2014, Chassanidis et al. , 2012, Campos et al., 2015). Observa-se que a exposição à nicotina levou à redução dos níveis de IL-4, -8 TNF-α, e OPG (Negri et al., 2016) e à diminuição dos níveis de mRNA de osteoprotegerina (OPN), COL-II, proteína morfogenética óssea 2 (BMP-2), sialoproteína óssea (BSP) e fator de ligação

do núcleo alfa-1 (Cbfa-1) (Yamano et al. 2010). Além disso, a fumaça do cigarro por si é uma fonte exógena e importante de espécies de oxigênio reativas (108 radicais livres orgânicos por sopro na fase gasosa e 1019 radicais livres por grama na fase do alcatrão) (Pryor, 1992, Babior, 1988, Bluhm & Weistein, 1971), que causam, por sua vez, estresse oxidativo celular, podendo afetar a expressão de moléculas de sinalização e a diferenciação de osteoblastos e osteoclastos (Xiao et al., 2003, Mensah et al., 2009).

Considerando tais fatos, a investigação de terapias com implantes mais previsíveis em pacientes fumantes poderia resultar em novas abordagens para contornar a influência nociva do fumo no reparo ósseo. Assim, macrogeometrias inovadoras de implantes com espaços estratégicos entre a superfície do implante e o leito cirúrgico ("câmaras de cicatrização") têm sido sugeridas como uma abordagem capaz de beneficiar os resultados relacionados à reparação peri-implantar (Freitas et al., 2012, Jimbo et al., 2014, Gehrke et al., 2020). A plausibilidade biológica desta modificação na macrogeometria de implantes baseia-se no fato de as câmaras de cicatrização serem preenchidas por coágulo imediatamente após a instalação do implante, contribuindo, desse modo, para o processo de reparo (Gehrke et al., 2020, Coelho et al., 2010, Marin et al., 2010). As configurações das câmaras de cicatrização têm sido relatadas como um aspecto importante para a estabilidade secundária e que não afeta a estabilidade primária (Gehrke et al., 2020, Gehrke et al., 2019, Ikar et al., 2020).

O contato próximo entre a superfície do implante e o leito ósseo é substancial para a estabilidade primária e subsequente osteointegração (Berglundh et al., 2003, Lioubavina-Hack et al., 2006), mas as evidências indicaram que esta condição pode promover a deterioração da cicatrização óssea peri-implantar pela extensa

reabsorção óssea que ocorre em torno do implante durante a cicatrização (Ikar et al., 2020, Campos et al., 2012, Monje et al., 2019).

Nesse sentido, é importante salientar que a formação óssea na presença de câmaras de cicatrização ocorre através da ossificação intramembranosa com nova formação óssea diretamente na superfície do implante e na parede óssea cirurgicamente instrumentada, o que reduz a ossificação aposicional e a reabsorção óssea devido à redução da necrose por compressão (Coelho & Jimbo, 2014). Nesse tipo de formação óssea, as câmaras de cicatrização são rapidamente preenchidas por osso tecido, que é posteriormente substituído por osso lamelar, que envolve múltiplas estruturas osteônicas primárias ao longo do volume da câmara de cicatrização. Além disso, modificações químicas na superfície do implante, tais como a presença de hidroxiapatias (HA), visam acelerar a resposta óssea e a possibilidade de reabilitação funcional em menos tempo, promovendo uma osteointegração mais rápida (Ellies et al. 1988; Gottlander et al. 1992) devido ao impacto osteocondutor da superfície (Coelho et al., 2009).

No passado, a camada de HA era espessa e descolada dos implantes, levando a várias complicações clínicas. Contudo, atualmente, a técnica de inserção à escala manométrica foi desenvolvida, promovendo uma integração celular eficaz sem sinais de reação de corpo estranho. Assim, existe um papel sinérgico das modificações nanotopográficas dos implantes e da composição química que conduzem a uma osteointegração acelerada (Jimbo et al. 2012). As alterações à escala nanométrica promoveram a diferenciação dos pré-osteoblastos, com níveis mais elevados de osteocalcina e expressão da osteoprotegerina *in vitro* (Gittens et al., 2011), e um estudo *in vivo* mostrou que os implantes contendo nanoestruturas apresentavam um maior contato osso-implante que os implantes polidos (de Lange et al., 1989).

Portanto, levando em consideração esses aspectos, constata-se que implantes com macrogeometria otimizada associados a modificações nanotopográficas poderiam beneficiar a terapia com implantes dentários na presença do tabagismo. Assim, este estudo avaliou pela primeira vez a influência de um implante com modificações tanto na macrogeometria como na nanotopografia, baseadas na presença de câmara de cicatrização e nanosuperfície ativada, sobre o padrão do reparo peri-implantar em na presença do tabagismo. Por fim, é importante ressaltar que uma melhor compreensão dos aspectos biomecânicos e dos mecanismos moleculares relacionados às modificações na macrogeometria em fumantes poderia embasar a utilização desta estratégia para favorecer a reabilitação com implantes dentários nesta condição.

2 ARTIGO

Este artigo será enviado para a revista:_____

Título do artigo: As modificações macro e microgeométricas dos implantes dentários podem influenciar o reparo ósseo peri-implantar em fumantes? Um ensaio clínico randomizado.

Óbice ALS, Girlanda FF, Correa MG, Ribeiro FV, Pimentel SP, Casati MZ, Cirano FR.

Andre Luis Seferian Óbice, DDS, MS [1]

Felipe Fonseca Girlanda, DDS, MS

Monica Grazieli Correa, DDS, MS, PHD, Professora

Fernanda Vieira Ribeiro, DDS, MS, PHD, Professora

Suzana Peres Pimentel, DDS, MS, PHD, Professora

Marcio Zaffalon Casati, DDS, MS, PhD, Professor

Fabiano Ribeiro Cirano, DDS, MS, PHD, Professor

[1]Dental Research Division, School of Dentistry, Universidade Paulista (UNIP), São Paulo, São Paulo, Brazil. Address: Av. Dr. Bacelar, 1212, 4º andar, Vila Clementino, São Paulo, SP - Brazil, CEP: 04026-002

Corresponding Author: Fabiano Ribeiro Cirano; Departamento de Odontologia, Universidade Paulista (UNIP), Av. Dr. Bacelar, 1212, Vila Clementino, São Paulo, Brasil, 04026-002. Número de telefone / fax: +55 (11) 5586-4000. E-mail: cirano.fabiano@gmail.com (e-mail e número de fax podem ser publicados).

May the macro and microgeometry modifications of dental implants influence peri-implant bone repair in smokers? A Randomized clinical trial.

Andre Luis Seferian Óbice, DDS, MS [1]

Felipe Fonseca Girlanda, DDS, MS

Mônica Grazieli Corrêa, DDS, MS, PHD, Professor

Fernanda Vieira Ribeiro, DDS, MS, PHD, Professor

Suzana Peres Pimentel, DDS, MS, PHD, Professor

Marcio Zaffalon Casati, DDS, MS, PhD, Professor

Fabiano Ribeiro Cirano, DDS, MS, PHD, Professor

Running title:

Correspondence: Fabiano Ribeiro Cirano; Departamento de Odontologia, Universidade Paulista (UNIP), Av. Dr. Bacelar, 1212, Vila Clementino, São Paulo, Brazil, 04026-002. Telephone/Fax number: +55 (11) 5586-4000. E-mail: e-mail: suppimentel@yahoo.com cirano.fabiano@gmail.com (E-mail and fax number can be published).

Keywords: dental implants, surface treatment, bone, biological markers, protein array

[1] Dental Research Division, School of Dentistry, Paulista University (UNIP), São Paulo, Brazil. Address: Av. Dr. Bacelar, 1212, 4º andar, Vila Clementino, São Paulo, SP - Brazil, CEP: 04026-002.

Abstract

This split-mouth, doble-blind, randomized clinical trial aimed at evaluating the impact of different macrogeometries and nanotopographical modifications on peri-implant bone repair in smokers. Thirty-two patients who smoked at least 10 cigarettes/day, with the need of a single maxillary or mandibular implant bilaterally, received two implants randomly assigned in two groups: DA - Dual Acid-Etched implants (n=32); HCAN – healing chambers and activated nanosurface (n=32). Implant stability quotient (ISQ) was evaluated at 07, 30, 60, 90 and 120 days after implant placement. Levels of Dickkopf-1 (DKK1), osteoprotegrin (OPG), ostopontin (OPN), vascular endothelial growth factor (VEGF), epidermal growth factor (EGF), fibroblast growth factor (FGF), placental growth factor (PlGF), osteocalcin (OC), bone morphogenetic protein-9 (BMP-9), tumor necrosis factor (TNF) alpha and receptor activator of nuclear factor-κB ligand (RANKL) were quantified in the peri-implant fluid after 07, 15, 30, 90 and 120 days of implant insertion. The ISQ was higher for HCAN implants at 60 days' time-point compared to DA implants ($p<0.05$). PLGF levels were lower for HCAN implants at 07 days period compared to DA implants ($p<0.05$). Besides, HCAN implants presented higher levels of OPG at 30 days period and OPN, BMP-9, FGF-1, PLGF and VEGF at 90 days period, when compared to DA implants ($p<0.04$). The levels of EGF were higher for HCAN implants at 15, 90 and 120 days-time point comparing with DA implants ($p<0.05$). HCAN implants also showed lower levels of TNF-α at 07 days' time-point ($p<0.05$) in comparison to DA implants ($p<0.05$) but had higher levels of DKK1 at 30-days' time-point in while DA implants presented higher level of this marker at 90 days' time-point ($p<0.05$). Macrogeometry and nanotopographical modifications positively modulated the bone and angiogenic factors resulting in higher production of these markers during early peri-implant bone healing and had positive effect on implant stabilization in smokers.

Introduction

Smoking has been considered as a risk factor for dental implant failure (Chen, Liu, Xu, Qu, & Lu, 2013; Chrcanovic, Albrektsson, & Wennerberg, 2015; Moraschini, 2016; Strietzel et al., 2007) and for peri-implantitis development (Heitz-Mayfield, 2008; Renvert & Quirynen, 2015; Pimentel et al., 2018). Moreover, it has been observed higher peri-implant marginal bone loss in smokers than in nonsmokers (Qian, Wennerberg, & Albrektsson, 2012) and heavy smokers may have higher incidence of implant failure (Alsaadi, Quirynen, Komarek, & van Steenberghe, 2007; Twito & Sade, 2014; van Steenberghe, Facobs, Desnyder, Maffei, & Quirynen, 2002). Additionally, epidemiologic studies have reported that smoking reduces bone density and increases bone fracture occurrence, leading to delayed bone repair and altered bone metabolism (Vestergaard & Mosekild, 2003, Giorgetti et al., 2010).

Some pathophysiologic mechanisms could help to explain the negative impact of cigarette smoking on peri-implant tissues, including alterations in important bone and angiogenic factors such as nuclear factor kappa-B (RANK), receptor activator of nuclear factor kappa-B ligand (RANKL), and osteoprotegerin (OPG) [RANK–RANKL–OPG system], bone morphogenetic proteins (BMPs), transforming growth factor-β (TGF-β) and alkaline phosphatase (ALP) (Ma et al., 2014, Chassanidis et al., 2012, Campos et al., 2015) and reduced the levels of IL-4, -8 TNF-α, and OPG (Negri et al., 2016). Additionally, exposure to nicotine lead to decrease of mRNA levels of osteoprotegerin (OPN), COL-II, Bone morphogenetic protein 2 (BMP-2), bone sialoprotein (BSP) and Core-binding factor alpha-1 (Cbfa-1) (Yamano et al. 2010). Furthermore, cigarette smoke itself is an exogenous and major source of reactive oxygen species (ROS) (108 organic free radicals per puff in the gas phase and 1019 free radicals per gram in the tar phase) (Pryor, 1992, Babior, 1988, Bluhm & Weistein, 1971), that cause cellular oxidative stress which can affect the expression of inflammatory signaling molecules and the differentiation of osteoblasts and osteoclasts (Xiao et al., 2003, Mensah et al., 2009).

Considering this, the investigation of more predictable implant therapies in smokers could result in new approaches to overcome the harmful influence of smoking on bone healing. Therefore, innovative implant macrogeometries with strategic spaces between the implant surface and the surgical bed ("healing chambers"), have been suggested as an approach able to benefit the results related to peri-implant repair (Freitas et al., 2012, Jimbo et al., 2014, Gehrke et al., 2020). The biological plausibility of this modification on implant macrogeometry is founded on the fact of healing chambers are filled by blood clot immediately after to implant installation, contributing to healing process (Gehrke et al., 2020, Coelho et al., 2010, Marin et al., 2010). Healing chamber configurations has been reported as an important aspect for secondary stability and may not affecting the primary

stability (Gehrke et al., 2020, Gehrke et al., 2019, Ikar et al., 2020). The near contact between the implant surface and the bone bed is substantial for primary stability and subsequent osseointegration (Berglundh et al., 2003, Lioubavina-Hack et al., 2006), but evidence have indicated that this condition may promote impairment on peri-implant bone healing by the extensive bone resorption that occurs around implant during healing (Ikar et al., 2020, Campos et al., 2012, Monje et al., 2019). It is important to highlight that bone formation in the presence of healing chambers occurs trough intramembranous ossification with new bone formation directly on the implant surface and at the surgically instrumented bone wall, which reduces appositional ossification and bone resorption due to the reduction on compression necrosis (Coelho & Jimbo, 2014). In this type of bone formation, the healing chambers are rapidly filled by woven bone, which is subsequently replaced by lamellar bone surrounding multiple primary osteonic structures throughout the healing chamber volume.

Additionally, chemical modifications on implant surface, such as the presence of hydroxyapathy (HA) aims at accelerating the bone response and the possibility of functional rehabilitation in shorter time by promoting a faster osseointegration (Ellies et al. 1988; Gottlander et al. 1992) due to the osteoconductive impact of the surface (Coelho et al., 2009). In the past, the HA layer was thick and could be detached from the implants along the time, leading to several clinical complications. However, currently, the insertion technique in a manometric scale has been developed, promoting effective cell integration without signs of foreign body reaction. Thus, there is a synergistic role of the nanotopographical modifications of implants and of the chemical composition leading to accelerated osseointegration (Jimbo et al. 2012). Nano-scale changes have promoted the differentiation of pre-osteoblasts, with higher levels of osteocalcin and osteoprotegerin expression in vitro (Gittens et al., 2011). Besides, an in vivo study showed that implants containing nanostructures presented higher bone-to-implant contact than polished implants (de Lange et al., 1989).

In this regard, implants with optimized macrogeometry associated with nanotopographical modifications could benefit the therapy with dental implants in the presence of smoking. Thus, this study evaluated for the first time the influence of an implant with modified macrodesign and nanotopographical modifications based on the presence of healing chamber and activated nanosurface in the pattern of peri-implant repair under smoking conditions. A better understanding of biomechanical aspects and of molecular mechanisms related to the use of modified implant macrodesign on smokers could support the use of this strategy to favor the rehabilitation with dental implants in this condition.

Materials and Methods

Population Screening

The population of the present prospective, randomised, double-blind, split mouth, and controlled clinical study was recruited from patients who sought dental treatment at Paulista University, São Paulo, Brazil, between February 2019 and January 2020. The clinical procedures and assessments were carried out between May 2019 and November 2020. Data entry and statistical analysis was performed in May 2021. The inclusion criteria in this study consisted of smokers (>10 cigarettes/day) aged between 18 and 65 years; presence of at least 20 teeth in the oral cavity and, bilateral and homologous unitary prosthetic space. The exclusion criteria were: the presence of systemic diseases that could interfere with bone regeneration (diabetes, arthritis, hypothyroidism, hyperparathyroidism, and osteoporosis); pregnancy or breastfeeding; use of medications that counter-indicated the performance of surgical procedures or that could alter bone regeneration around implants (e.g., anti-inflammatory and bisphosphonate drugs).; absence of keratinized tissue at the implant insertion sites (may interfere with hygiene around the implants); need for bone or tissue grafts. All the participants were informed about the nature, potential risks, and benefits of their participation in the study, and signed an informed consent form. This study was approved by the Research Ethics Committee of Paulista University (80794517.8.0000.5512) and presented CONSORT-based design.

Sample Size Calculation

The number of patients included in the present study was based on previous studies that had found significant differences in the levels of bone, angiogenic, and inflammatory markers in peri-implant fluid (Verrastro-Neto et al., 2017; Óbice et al., 2018). The calculation yielded a minimum sample size of 18 participants per group. Considering that several individuals and implants may be lost throughout follow-up, 32 individuals were included in each group.

Randomization

Patients were randomly assigned, using a computer-generated list generated a priori by a team member not involved in the clinical procedures, to one of the two treatment modalities: • DA - Dual Acid-Etched implants – single thread design (SW - S.I.N. IMPLANT SYSTEM) (n=32); • HCAN – healing chambers + dual thread design [thread within thread profile] and activated nanosurface - nano-sized HA according to the

Promimic HAnano™ method (Jimbo et al., 2012) (UNITITE - S.I.N. IMPLANT SYSTEM) (n=32).The flowchart of the study is described in Figure 1.

Treatment Protocol – implant placement

All the surgeries and post-operative follow-ups were performed by the same surgeon (A. L. S. O.) at the Dentistry Clinic of Paulista University, São Paulo, Brazil. All the patients received two cone morse connection implants in one stage, (S.I.N. IMPLANT SYSTEM, São Paulo, Brazil), which had their prosthetic platform positioned 2 mm below the bone crest after the installation of the implants with insertion torque varying from 30 to 45N. One side received a DA (Dual Acid-Etched implant) and the other, a HCAN (healing chambers and activated nanosurface). Hexagonal conical abutments and conical abutment protectors (Implacil de Bortoli, São Paulo, Brazil) were installed.

After anaesthesia, an incision in the centre of the bone crest was performed and a mucoperiosteal flap was shifted. The preparation of the site was done following the manufacturer instructions and, subsequently, the intermediate implants, and abutment protectors were installed. Uninterrupted sutures were performed using 4.0 nylon (Nylon, Ethicon, Somerville, New Jersey, USA). Amoxicillin (2 g administered one hour before the procedure), sodium dipyrone (500 mg every six hours for two post-operative days), and mouthwash with 0.12% chlorhexidine digluconate (every 12 hours for seven days) were indicated. All patients received single prostheses within 90 days of implant placement.

Dental Implant Stability Assessment

The implant stability quotient (ISQ) was determined by resonance frequency measurements using Osstell® (Integration Diagnostics AB, Göteborg, DAeden) at implant placement and at 30, 60, 90 and 120 days later. The measurements were performed in triplicate by the same examiner (A.S.O).

Fluid collection and evaluation of osteoblastogenic and angiogenic markers

Peri-implant fluids collection was performed by a blinded examiner in each group, using filter paper strips (Periopaper; Oraflow, Plainview, New York, USA), at baseline, 15, 30, 90 and 120 days after implant installation. The levels of bone and angiogenic mediators (of Dickkopf-1 (DKK1), osteoprotegrin (OPG), ostopontin (OPN), vascular endothelial growth factor (VEGF), Sclerostin (SOST), epidermal growth factor (EGF), fibroblast growth factor (FGF), placental growth factor (PlGF), osteocalcin (OC), bone morphogenetic protein-9 (BMP-9), tumor necrosis factor (TNF) alpha and receptor activator of nuclear factor-κB ligand (RANKL) were determined using

a specific kit (HAGP1MAG-12K, HRNKL-51K, HRNMAG-51K, Millipore Corporation, Billerica, MA, USA), and measured with a multiplex instrument (MAGpixTM; MiraiBio, Alameda, CA, USA), following the manufacturers' instructions. The samples were individually evaluated, adjusted for the fluid volume, and the concentrations were estimated from the standard curve using a five-parameter polynomial equation and specific software (Xponent® Millipore Corporation, Billerica, MA, USA). The mean concentration of each biomarker was calculated and expressed as pg/ml.

Statistical analysis

The primary outcome variable was the biomarkers levels. The secondary outcomes was ISQ. Initially, the data were submitted to tests for normality (Shapiro-Wilk test). Once the distribution of data was not normally, ISQ data and immunoenzymatic markers were submitted to Wilcoxon and Friedman test (inter and intra-group analysis, respectively). An experimental level of significance was established at 5% for all statistical analyses. The biostatistician was blinded to the treatment allocation of the quadrants. The analyses were performed using SAS 9.3 software (SAS Institute Inc., Cary, NC, USA).

Results

Initially, 74 patients were recruited; however, 42 of them were excluded, because they did not meet the inclusion criteria. This way, 32 individuals were included in the present study and no patients withdrew during the experimental stage (Figure 2). Table 1 shows the data concerning sex, age, and implants' distribution, and no statistically significant differences were observed ($p > .05$).

Resonance Frequency Analysis

In the resonance frequency analysis, the implant stability quotient (ISQ) presented higher values for HCAN implants at 60-day time-point ($p<0.05$). Intragroup analysis showed higher ISQ values at 120 days' time-point compared to 30 days period in HCAN group ($p<0.05$), while DA group presented higher values at 90 and 120 days compared to 30 days period ($P<0.05$). The data regarding ISQ are summarized in Figure 3.

Immunoenzymatic markers levels

The immunoenzymatic results are illustrated in Figure 4. Immunoenzymatic assay for bone and angiogenic markers showed for intergroup analysis that HCAN implants demonstrated higher levels of DKK1 at 30 days' time-point in while DA implants presented higher level of this marker at 90 days' time-point ($p<0.05$). HCAN implants presented higher levels of OPG at 30 days period and OPN, BMP-9, FGF-1 and VEGF at 90 days period, when compared to DA implants ($p<0.05$). The levels of EGF were higher for HCAN implants at 15-, 90- and 120-days period comparing to DA implants ($p<0.05$). HCAN implants also showed lower levels PLGF and VEGF at 07 days' time-point and lower levels of SOST at 30 days' time-point in comparison to DA implants ($p<0.05$). However, the levels of PLGF were higher for HCAN implants at 90-day time-point ($p<0.05$). HCAN implants had lower levels of TNF-α at 07 days' time-point ($p<0.05$). There was not statistically difference intergroup for OC and RANKL ($p>0.05$).

As regards to intragroup analysis of HCAN implants, it was observed higher levels of DKK1 30- and 120-days' time-point compared to 07 days and at 30 days compared to 15 days period ($p<0.05$). OPG, OPN, BMP-9 and VEGF at 30-, 90- and 120-days' time-point compared to 07 days' time-point ($p<0.05$). Besides, the levels of VEGF were higher at 15 days' time-point compared to 07 days' time-point ($p<0.05$) and thirty days-period showed elevated levels of OPG when compared to 15 days' time-point ($p<0.05$). HCAN implants presented higher levels of EGF and PLGF at 15, 30 and 90 days-period compared to 07 days' time-point ($p<0.05$). The levels of FGF-1 were higher at 30 and 90 days-period compared to 15 days ($p<0.05$). The levels of TNF-α were higher at 30 and 90 days-period when compared to 07 days' time-point, and at 30 days compared to 15 days' time-point ($p<0.05$). RANKL levels were higher at 90 days' time-point when compared to 15 days period ($p<0.05$). HCAN implants did not present intragroup difference for OC and SOST ($p>0.05$).

Considering the intragroup analyses for DA implants, higher levels of DKK1 were observed at 90 days-period when compared to 07 and to 15 days' time-point($p<0.05$). DA implants also showed higher levels of OPG at 90 and 120 days-period comparing to 15 days period ($p<0.05$). Higher levels of FGF-1 were observed at 30- and 90-days' time-point when compared to 120-day period ($p<0.05$). Higher levels of SOST and PLGF were observed at 30 days' time-period in comparison to 07 and 120 days-period ($p<0.05$). DA implants had higher levels of BMP-9 at 30 days-period comparing to 07 days period ($p<0.05$). The levels of EGF were higher at 30 and 90 days, when compared to 120 days-period ($p<0.05$). It was also showed elevated levels of FGF-1 and RANKL at 30, 90 and 120 days when compared to 07 days' time-point ($p<0.05$). The levels of RANKL were also

higher at 30- and 120-days' time-point compared to 15 days period ($p<0.05$). DA implants did not present intragroup difference for TNF-α, OC, OPN, and VEGF ($p>0.05$).

Discussion

Modifications of macrogeometry and nanotopography of implants, such as healing chambers and nanoactivated modifications have been suggested as an approach to enhance peri-implant repair, to accelerate osseointegration, leading to higher bone-implant contact and implant stability, suggesting the possibility of faster prosthetic loading. In face of that, this could be an interesting approach for patients with compromised bone quality and repair, such as smokers. Within the author's knowledge, there is no clinical study evaluating peri-implant bone healing and stability using an implant with modified macrodesign and activated nanosurface under smoking conditions. In general, the present study showed higher levels of bone and angiogenic factors and higher implant stability at early bone healing phases.

In this trial, resonance frequency analysis was performed during implant insertion and after 30, 60 90 and 120 days of implant installation. Although intergroup difference has been observed only at 60 days period, with higher levels of ISQ for HCAN implants, it can be suggested that the implant modifications on the macrogeometry and nanotopography could benefit implant stability in the presence of a systemic condition that leads to impaired bone repair. A recent trial comparing implant stability in smokers and nonsmokers showed a decrease in secondary stability with smoking habit, with a difference of 3.61 points between smokers and nonsmokers (Badenes-Catalán & Pallarés-Sabater, 2021). In line, another study, comparing implant stability between nonsmokers and heavy smokers, demonstrated that bone healing around dental implants was decreased due to a reduced healing speed, indicating that the time to apply implant loading in heavy smokers is important (Sun et al., 2016). In our study, although the ISQ differed between groups only at 60 days period, the levels of implant stability in both groups were stable until 120 days, suggesting that the modifications on the macrogeometry and nanotopography could have helped contributing for increase bone healing, preventing ISQ levels decrease throughout the time and that the implant loading could be applied safely for both groups. In fact, dual acid-etched implants have shown higher success rate in bone with lower quality, reducing healing time and allowing earlier implant loading and rehabilitation (Lazzara et al., 1998). Another study showed higher success rate for dual acid-etched implants compared to machined implants in poor quality bone (12% of difference) (Khang et al., 2001). Although these studies did not compare the success rate of dual acid-etched implants between smoker and nonsmoker patients, it is known that smoking condition affects bone density (Vestergaard & Mosekild, 2003, Nociti et al., 2002a) and

bone quality (Nociti et al., 2002b) and these results could be extrapolated to a clinical situation where smoking is present.

Important bone-related factors such as DKK1 and OPG had elevated levels in the presence of macro and nanotopographical modifications at 30 days after implant installation. In contrast, DKK1 levels were higher in DA implants at 90 days. DKK1 is responsible for suppress osteoblast differentiation and facilitate osteoclastogenesis (Whang et al., 2016, Chen et al, 2015) and OPG inhibits the differentiation and function of osteoclasts (Wdagawa et al., 2000), modulating bone maturation and resorption (Belibasakis & Bostanci, 2012). On the other hand, there is no difference between the groups regarding RANKL levels, but lower levels of TNF-α were found in HCAN implants at 07 days period. Interestingly, a previous study of our research group showed higher levels of mRNA of RANKL/OPG in the bone tissue around implants inserted in rats submitted to the cigarette smoking inhalation than in non-smoking animals (Ribeiro et al., 2018). An in vitro study showed that nano-scale changes enhanced the differentiation of pre-osteoblasts, which showed significantly higher levels of OC and OPG expression (Gittens et al.,2011). However, the present study did not observe any intergroup difference in OC levels. Even though, it is known some pathways through smoking negatively affects some bone factors, such as RANKL/OPG system (Lappin et al., 2007), no data is available about modulation of DKK1 by cigarette smoking. As regards to TNF-α levels in smokers, it was verified higher levels in the gingival crevicular fluid when compared to nonsmokers (Giannopoulou et al., 2003) and it could be attribute to the potent inhibitors contained in smoke of both gene expression and protein production for this marker (Morozumi et al., 2004).

In line, the concentration of OPN and EGF was higher at 90 days period in the presence of macro and microgeometry modifications. OPN is related to the binding of basic elements to the extracellular bone matrix and bone mineralization (McKee et al., 2011) and regulates angiogenesis as a response to cell stress, cell adhesion, chemotaxis, and cell motility (Wai & Kuo, 2004). Interestingly, osteoblasts seeded onto HA treated surfaces had higher expression of OPN when compared with the DAE surface (Martinez et al., 2018). Convergently, EGF acts in differentiation and mineralization of osteoblast differentiation, DNA synthesis, growth and proliferation of mesenchymal cells, angiogenesis, stimulation of vascular permeability, tissue proliferation and faster tissue regeneration during the initial peri-implant bone regeneration phases (Adam et al., 2017, Alves et al., 2009, Sezer et al., 2001). This marker was also elevated for HCAN implants at 15 and 120 days after implant placement. Taken together, these results are important findings of this trial once bone density in the presence of smoking is reduced (Nociti et al., 2002a), and this may favor both bone quality and anticipate implant loading time.

BMP-9 and FGF-1 presented higher concentration with the use of macro and nanotopographical modification at 90 days' time-point. BMP-9 has the highest osteogenic activity among bone morphogenetic protein, acting in the differentiation of mesenchymal cells into osteoblasts (Peng et al., 2003, Peng et al., 2004). The higher levels of the marker FGF-1 probably contributed to a faster bone healing around HCAN implants, since its function includes fibroblasts, endothelial cells, and osteoblasts proliferation (Montero et al., 2000, Sato et al., 1991), induction of angiogenesis and the expression of proteases, growth factors, and integrins involved in angiogenesis (Chim et al., 2013). The elevated concentration of both markers at early phases of healing may accelerate bone healing due to their action on regeneration, chemical attraction, proliferation, and cell differentiation into osteoblasts (Luginbuehl et al., 2004

Interestingly, the levels of VEGF and PLGF were elevated in the presence of implant design modifications at 90 days period. Both are angiogenic factors linked to osteoclasts, osteoblasts and chondroblasts differentiation (Li et al., 64), and proliferation, migration, and survival of endothelial cells (Adini et al., 2002). These results indicate pronounced angiogenic activity with modifications of macro and microgeometry of implants, favoring the healing process around the implants.

In line, the results concerning bone and angiogenic markers show, in general way, higher concentration of most of the studied markers at 30- and 90-days period, which can help to explain the results regarding ISQ level (higher values for HCAN implants at 60 days). In this study, bone and angiogenic markers were not measured at 60 days' time-point and maybe if the measurement had been done, it could be observed higher concentration of the markers also at this point.

Another interesting point to be highlighted is the reduction in most of the studied markers from the 90- to the 120-day time-period and this reduction could be associated with implant loading at 90-day time-point. In line, Prati et al. (2013) evaluated the pattern of bone markers release during peri-implant bone repair of immediately loaded and nonloaded implants, observing earlier peak of TGF, OPG, OPN, and parathyroid hormone in loaded implants.

The benefits of implant design with modified macrogeometry have been reported in some investigations. Recently, a preclinical trial demonstrated histological and clinical evidence supporting the safety and efficacy of an implant design with modified macrogeometry capable of obtaining promising primary and secondary stability in alveoli after immediate extraction, without the use of bone grafts (Nevins et al ., 2019). Studies were also carried out to point out the interference of the use of chemical agents on the implant surface and showed promising results in relation to the macro geometry of the implants, regardless of the surface treatment given to the implants (Gehrke

et al., 2019b). Recent animal studies have proven the effectiveness of a modified macrogeometry after a short initial repair period using a counter-torque method (Gehrke et al., 2019b).

It has been shown the positive effect of nanotopography in cell activity due to the interactions among cell, matrix and substrate associated with cell signaling happen at the nanometer stage (Curtis & Wilkinson, 1999), which results in regulation of cell migration, proliferation, adhesion, spreading, and differentiation and both gene and protein expression (Globus et al., 1995, Shneider et al., 2001). This results in a biological response to the material and accelerated healing and osseointegration (Dang et al., 2016, Longo et al 2016).

A limitation of this study could be the lack of a machined implant to better evaluate the pattern of the bone- and angiogenic-related markers release in peri-implant bone tissue in smokers. It can be also pointed that it is not possible to know the specific effect of the macrogeometry and nanotophographical modifications on the release of immunoenzymatic markers evaluated, as well as in implant stability. The results found in this study could be due to one or another design modification or due to the synergistic effect of both.

The results of this trial are important to elucidate the molecular mechanisms in early phases of bone healing around implants with macrogeometry and nontopographical modifications, showing the possibility of a faster osseointegration process and implant loading, also allowing a faster rehabilitation process in smokers patients. However, further studies are necessary to verify the behavior of tissues after implant loading in terms of clinical parameters, release of inflammatory markers and bacterial colonization throughout the time.

Taken together, the results of the present study showed that macrodesign modification and nonactivated surface enhanced bone repair during the early phases of osseointegration, with lower bone resorption and higher implant stability in the presence of the negative effects of cigarette smoking. Thus, in conclusion, the implant macrogeometry modification associated to nonactivated surface positively modulated bone and angiogenic factors and improved implant stability in early osseointegration phase in smokers.

Acknowledgements

This study was supported S.I.N (IMPLANT SYSTEM). The authors declare no potential conflicts of interest with respect to the authorship and/or publication of this article.

References

1. Chen H, Liu N, Xu X, Qu X, Lu E. Smoking, radiotherapy, diabetes and osteoporosis as risk factors for dental implant failure: a meta-analysis. PLoS One. 2013 Aug 5;8(8):e71955. doi: 10.1371/journal.pone.0071955. PMID: 23940794; PMCID: PMC3733795.
2. Chrcanovic BR, Albrektsson T, Wennerberg A. Smoking and dental implants: A systematic review and meta-analysis. J Dent. 2015 May;43(5):487-98. doi: 10.1016/j.jdent.2015.03.003. Epub 2015 Mar 14. PMID: 25778741.
3. Moraschini V, Barboza Ed. Success of dental implants in smokers and non-smokers: a systematic review and meta-analysis. Int J Oral Maxillofac Surg. 2016 Feb;45(2):205-15. doi: 10.1016/j.ijom.2015.08.996. Epub 2015 Sep 15. PMID: 26385308.
4. Strietzel FP, Reichart PA, Kale A, Kulkarni M, Wegner B, Küchler I. Smoking interferes with the prognosis of dental implant treatment: a systematic review and meta-analysis. J Clin Periodontol. 2007 Jun;34(6):523-44. doi: 10.1111/j.1600-051X.2007.01083.x. PMID: 17509093.
5. Heitz-Mayfield LJ. Peri-implant diseases: diagnosis and risk indicators. J Clin Periodontol. 2008 Sep;35(8 Suppl):292-304. doi: 10.1111/j.1600-051X.2008.01275.x. PMID: 18724857.
6. Renvert S, Quirynen M. Risk indicators for peri-implantitis. A narrative review. Clin Oral Implants Res. 2015 Sep;26 Suppl 11:15-44. doi: 10.1111/clr.12636. PMID: 26385619.
7. Pimentel SP, Shiota R, Cirano FR, Casarin RCV, Pecorari VGA, Casati MZ, Haas AN, Ribeiro FV. Occurrence of peri-implant diseases and risk indicators at the patient and implant levels: A multilevel cross-sectional study. J Periodontol. 2018 Sep;89(9):1091-1100.
8. Qian J, Wennerberg A, Albrektsson T. Reasons for marginal bone loss around oral implants. Clin Implant Dent Relat Res. 2012 Dec;14(6):792-807. doi: 10.1111/cid.12014. Epub 2012 Nov 30. PMID: 23198697.
9. Alsaadi G, Quirynen M, Komárek A, van Steenberghe D. Impact of local and systemic factors on the incidence of late oral implant loss. Clin Oral Implants Res. 2008 Jul;19(7):670-6. doi: 10.1111/j.1600-0501.2008.01534.x. Epub 2008 May 19. PMID: 18492080.
10. Twito D, Sade P. The effect of cigarette smoking habits on the outcome of dental implant treatment. PeerJ. 2014 Sep 2;2:e546. doi: 10.7717/peerj.546. PMID: 25237600; PMCID: PMC4157230.
11. van Steenberghe D, Jacobs R, Desnyder M, Maffei G, Quirynen M. The relative impact of local and endogenous patient-related factors on implant failure up to the abutment stage. Clin Oral Implants Res. 2002 Dec;13(6):617-22. doi: 10.1034/j.1600-0501.2002.130607.x. PMID: 12519336.

12. Ma T, Tan MS, Yu JT, Tan L. Resveratrol as a Therapeutic Agent for Alzheimer's Disease. Biomed Res Int 2014: 2014: 350516. doi: 10.1155/2014/350516.
13. Chassanidis CG, Malizos KN, Varitimidis S, Samara S, Koromila T, Kollia P, Dailiana Z. Smoking affects mRNA expression of bone morphogenetic proteins in human periosteum. J Bone Joint Surg Br 2012: 94: 1427-32.
14. Campos JM, Prati AJ, Cirano FR, Pimentel SP, Pastore GP, Pecorari VG, Ribeiro FV, Casati MZ, Casarin RC. Smoking Modulates Gene Expression of Type I Collagen, Bone Sialoprotein, and Osteocalcin in Human Alveolar Bone. J Oral Maxillofac Surg 2015: 73: 2123-31. doi: 10.1016/j.joms.2015.06.168.
15. Negri BM, Pimentel SP, Casati MZ, Cirano FR, Casarin RC, Ribeiro FV. Impact of a chronic smoking habit on the osteo-immunoinflammatory mediators in the peri-implant fluid of clinically healthy dental implants. Arch Oral Biol. 2016 Oct;70:55-61. doi: 10.1016/j.archoralbio.2016.05.014. Epub 2016 Jun 7. PMID: 27328151.
16. Coelho PG, Granjeiro JM, Romanos GE, Suzuki M, Silva NR, Cardaropoli G, Thompson VP, Lemons JE. Basic research methods and current trends of dental implant surfaces. J Biomed Mater Res B Appl Biomater 2009;88(2):579-96.
17. Gittens RA, McLachlan T, Olivares-Navarrete R, Cai Y, Berner S, Tannenbaum R, Schwartz Z, Sandhage KH, Boyan BD. The effects of combined micron-/submicron-scale surface roughness and nanoscale features on cell proliferation and differentiation. Biomaterials 2011;32(13):3395-403.
18. de Lange GL, Donath K. Interface between bone tissue and implants of solid hydroxyapatite or hydroxyapatite-coated titanium implants. Biomaterials 1989;10(2):121-5.
19. Yamano S, Berley JA, Kuo WP, Gallucci GO, Weber HP, Sukotjo C. Effects of nicotine on gene expression and osseointegration in rats. Clin Oral Implants Res 2010: 21: 1353-9. doi: 10.1111/j.1600-0501.2010.01955.x.
20. Pryor WA. Biological effects of cigarette smoke, wood smoke and the smoke from plastics: the use of electron spin resonance. Free Rad Biol Med 1992;13:659–676.
21. Babior BM. The respiratory burst oxidase. Hematol Oncol Clin N Am 1988;2:201–212.
22. Bluhm AC, Weistein J, Sonsa JA. Free radicals in tobacco smoke. Nature 1971;229:500.
23. Xiao GG, Wang M, Li N, Loo JA, Nel AE. Use of proteomics to demonstrate a hierarchical oxidative stress response to diesel exhaust particle chemicals in a macrophage cell line. J Biol Chem 2003: 278: 50781-90.

24. Mensah KA, Li J, Schwarz EM. The emerging field of osteoimmunology. Immunol Res 2009: 45: 100-13. doi: 10.1007/s12026-009-8093-x.

25. Yildiz D. Nicotine, its metabolism and an overview of its biological effects. Toxicon. 2004 May;43(6):619-32. doi: 10.1016/j.toxicon.2004.01.017. PMID: 15109883.

26. Albrektsson T, Brånemark PI, Hansson HA, Lindström J. Osseointegrated titanium implants. Requirements for ensuring a long-lasting, direct bone-to-implant anchorage in man. Acta Orthop Scand. 1981;52(2):155-70. doi: 10.3109/17453678108991776. PMID: 7246093.

27. Albrektsson T, Wennerberg A. Oral implant surfaces: Part 2--review focusing on clinical knowledge of different surfaces. Int J Prosthodont. 2004 Sep-Oct;17(5):544-64. PMID: 15543911.

28. Albrektsson T, Wennerberg A. Oral implant surfaces: Part 1--review focusing on topographic and chemical properties of different surfaces and in vivo responses to them. Int J Prosthodont. 2004 Sep-Oct;17(5):536-43. PMID: 15543910.

29. Shibli JA, Feres M, de Figueiredo LC, Iezzi G, Piattelli A. Histological comparison of bone to implant contact in two types of dental implant surfaces: a single case study. J Contemp Dent Pract. 2007 Mar 1;8(3):29-36. PMID: 17351679.

30. Shibli JA, Grassi S, de Figueiredo LC, Feres M, Marcantonio E Jr, Iezzi G, Piattelli A. Influence of implant surface topography on early osseointegration: a histological study in human jaws. J Biomed Mater Res B Appl Biomater. 2007 Feb;80(2):377-85. doi: 10.1002/jbm.b.30608. PMID: 16850464.

31. Shibli JA, Grassi S, Piattelli A, Pecora GE, Ferrari DS, Onuma T, d'Avila S, Coelho PG, Barros R, Iezzi G. Histomorphometric evaluation of bioceramic molecular impregnated and dual acid-etched implant surfaces in the human posterior maxilla. Clin Implant Dent Relat Res. 2010 Dec;12(4):281-8. doi: 10.1111/j.1708-8208.2009.00174.x. PMID: 19438956.

32. Puleo DA, Nanci A. Understanding and controlling the bone-implant interface. Biomaterials. 1999 Dec;20(23-24):2311-21. doi: 10.1016/s0142-9612(99)00160-x. PMID: 10614937.

33. Davies JE. Bone bonding at natural and biomaterial surfaces. Biomaterials. 2007 Dec;28(34):5058-67. doi: 10.1016/j.biomaterials.2007.07.049. Epub 2007 Aug 13. PMID: 17697711.

34. Freitas ACJ, Bonfante EA, Giro G et al. The effect of implant design on insertion torque and immediate micromotion. *Clin Oral Implants Res* 2012,23:113–118.

35. Jimbo R, Tovar N, Anchieta RB, et al. The combined effects of undersized drilling and implant macrogeometry on bone healing around dental implants: an experimental study. *Int J Oral Maxillofac Surg* 2014;43:1269–1275.

36. Gehrke SA, Tumedei M, Aramburú Júnior J, et al. Histological and Histomorphometrical Evaluation of a New Implant Macrogeometry. A Sheep Study. *Int J Environ Res Public Health* 2020;17:3477.

37. Coelho PG, Suzuki M, Guimaraes MVM, et al. Early bone healing around different implant bulk designs and surgical techniques: a study in dogs. *Clin Implant Dent Relat Res* 2010; 12:202–208.

38. Marin C, Granato R, Suzuki M, Gil JN, JanalMN, Coelho PG. Histomorphologic and histomorphometric evaluation of various endosseous implant healing chamber configurations at early implantation times: a study in dogs. *Clin Oral Implants Res* 2010;21:577–583

39. Gehrke SA, Eliers Treichel TL, et al. Impact of Different Titanium Implant Thread Animal Model. *J Clin Med* 2019; 31: 6.

40. Ikar M, Grobecker-Karl T, Karl M, Steiner C. Mechanical stress during implant surgery and its effects on marginal bone: a literature review. *Quintessence Int* 2020;51:142-150.

41. Berglundh T, Abrahamsson I, Lang NP, Lindhe J. De novo alveolar bone formation adjacent to endosseous implants. *Clin Oral Implants Res* 2003;14:251-262.

42. Lioubavina-Hack N, Lang NP, Karring T. Significance of primary stability for osseointegration of dental implants. *Clin Oral Implants Res* 2006;17:244-250

43. Campos FE, Gomes JB, Marin C, et al. Effect of drilling dimension on implant placement torque and early osseointegration stages: An experimental study in dogs. *J Oral Maxillofac Surg* 2012, 70, e43–e50.

44. Monje A, Ravidà A, Wang HL, Helms JA, Brunski JB. Relationship Between Primary/Mechanical and Secondary/Biological Implant Stability. *Int J Oral Maxillofac Implants* 2019;34:s7-s23.

45. Óbice ALS, Correa MG, Feng HS, Ribeiro FV, Cirano FR, Casati MZ, Pimentel SP. The impact of implant abutment surface treatment with TiO2 on peri-implant levels of angiogenesis and bone-related markers: a randomized clinical trial. Int J Oral Maxillofac Surg. 2019 Jul;48(7):962-970. doi: 10.1016/j.ijom.2018.12.012. Epub 2019 Jan 17. PMID: 30661944.

46. Verrastro Neto A, Andrade R, Corrêa MG, Casarin RCV, Casati MZ, Pimentel SP, Ribeiro FV, Cirano FR. The impact of different torques for the insertion of immediately loaded implants on the peri-implant levels of angiogenesis- and bone-related markers. Int J Oral Maxillofac Surg. 2018 May;47(5):651-657. doi: 10.1016/j.ijom.2017.11.001. Epub 2017 Nov 23. PMID: 29173997.

47. Vestergaard P, Mosekilde L: Fracture risk associated with smoking: A meta-analysis. J Intern Med 254:572, 2003

48. Giorgetti AP, Cesar Neto JB, Ruiz KG, et al: Cigarette smoke inhalation modulates gene expression in sites of bone healing: A study in rats. Oral Surg Oral Med Oral Pathol Oral Radiol Endod 110:447, 2010

49. Badenes-Catalán J, Pallarés-Sabater A. Influence of Smoking on Dental Implant Osseointegration: A Radiofrequency Analysis of 194 Implants. J Oral Implantol. 2021 Apr 1;47(2):110-117. doi: 10.1563/aaid-joi-D-19-00223. PMID: 32699886.

50. Sun C, Zhao J, Jianghao C, Hong T. Effect of Heavy Smoking on Dental Implants Placed in Male Patients Posterior Mandibles: A Prospective Clinical Study. J Oral Implantol. 2016 Dec;42(6):477-483. doi: 10.1563/aaid-joi-D-16-00078. Epub 2016 Aug 19. PMID: 27541691.

51. Lazzara RJ, Porter SS, Testori T, Galante J, Zetterqvist L. A prospective multicenter study evaluating loading of osseotite implants two months after placement: one-year results. J Esthet Dent. 1998;10(6):280-9. doi: 10.1111/j.1708-8240.1998.tb00505.x. PMID: 10321197.

52. Khang W, Feldman S, Hawley CE, Gunsolley J. A multi-center study comparing dual acid-etched and machined-surfaced implants in various bone qualities. J Periodontol. 2001 Oct;72(10):1384-90. doi: 10.1902/jop.2001.72.10.1384. PMID: 11699480.

53. Udagawa N, Takahashi N, Yasuda H, Mizuno A, Itoh K, Ueno Y, Shinki T, Gillespie MT, Martin TJ, Higashio K, Suda T. Osteoprotegerin produced by osteoblasts is an important regulator in osteoclast devel- opment and function. Endocrinology 2000;141:3478–84.

54. Ribeiro FV, Pimentel SP, Corrêa MG, Bortoli JP, Messora MR, Casati MZ. Resveratrol reverses the negative effect of smoking on peri-implant repair in the tibia of rats. Clin Oral Implants Res. 2019 Jan;30(1):1-10. doi: 10.1111/clr.13384. Epub 2018 Dec 26. PMID: 30402971.

55. Lappin Lappin DF, Sherrabeh S, Jenkins WM, Macpherson LM. Effect of smoking on serum RANKL and OPG in sex, age and clinically matched supportive-therapy periodontitis patients. J Clin Periodontol 2007:34: 271–277.

56. Wang D, Li SP, Fu JS, Bai L, Guo L. Resveratrol augments therapeutic efficiency of mouse bone marrow mesenchymal stem cell-based therapy in experimental autoimmune encephalomyelitis. Int J Dev Neurosci 2016; 49:, 60-66.

57. Chen H, Xu X, Liu M, et al. Sclerostin antibody treatment causes greater alveolar crest height and bone mass in an ovariectomized rat model of localized periodontitis. Bone 2015; 76: 141-148.

58. Belibasakis GN, Bostanci N. The RANKL-OPG system in clinical periodontology. J Clin Periodontol 2012; 39:239– 248.

59. McKee MD, Pedraza CE, Kaartinen MT. Osteopontin and wound healing in bone. Cells Tissues Organs 2011; 194:313– 319.

60. Luginbuehl V, Meinel L, Merkle HP, Gander B. Localized delivery of growth factors for bone repair. Eur J Pharm Biopharm 2004;58:197–208.

61. Adam AB, O¨ zdamar MY, Esen HH, Gu¨nel E. Local effects of epidermal growth factor on the wound healing in esophageal anastomosis: an experimental study. Int J Pediatr Otorhinolaryngol 2017;99:8–12.

62. Alves JB, Ferreira CL, Martins AF, Silva GA, Alves GD, Paulino TP, Ciancaglini P, Thedei Jr G, Napimoga MH. Local delivery of EGF-liposome mediated bone modeling in orthodontic tooth movement by increasing RANKL expression. Life Sci 2009;4:693–9.

63. Sezer O, Niemo¨ ller K, Jakob C, Zavrski I, Heider U, Eucker J, Kaufmann O, Possinger K. Relationship between bone marrow angiogenesis and plasma cell infiltration and serum beta2-microglobulin levels in patients with multiple myeloma. Ann Hematol 2001;80:598–601.

64. Peng Y, Kang Q, Cheng H, Li X, Sun MH, Jiang W, Luu HH, Luo J, Szatkowski JP, Vanichakarn P, Park JY, Li Y, Haydon RC, He TC. Transcriptional characterization of bone morphogenetic proteins (BMPs)-medi-ated osteogenic signaling. J Cell Biochem 2003;90:1149–65.

65. Peng Y, Kang Q, Luo Q, Jiang W, Si W, Liu BA, Luu HH, Park JK, Li X, Luo J, Montag AG, Haydon RC, He TC. Inhibitor of DNA binding/differentiation helix-loop-helix proteins mediate bone morphogenetic proteininduced osteoblast differentiation of mesenchymal stem cells. J Biol Chem 2004;279:32941–9.

66. Montero A, Okada Y, Tomita M, Ito M, Tsurukami H, Nakamura T, Doetschman T, Coffin JD, Hurley MM. Disruption of the fibroblast growth factor-2 gene results in decreased bone mass and bone formation. J Clin Invest 2000;105:1085–93.

67. Sato Y, Shimada T, Takaki R. Autocrinological role of basic fibroblast growth factor on tube formation of vascular endothelial cells in vitro. Biochem Biophys Res Commun 1991;180:1098–102.

68. Chim SM, Tickner J, Chow ST, Kuek V, Guo B, Zhang G, Rosen V, Erber W, Xu J. Angiogenic factors in bone local environment. Cytokine Growth Factor Rev 2013;24:297–310.

69. Li R, Stewart DJ, von Schroeder HP, Mack- innon ES, SchemitschEH. Effect of cell-based VEGF gene therapy on healing of a segmental bone defect. J Orthop Res 2009;27:8–14.

70. Adini A, Kornaga T, Firoozbakht F, Benja-min LE. Placental growth factor is a survival factor for tumor endothelial cells and macro-phages. Cancer Res 2002;62:2749–52.

71. Wai PY, Kuo PC. The role of Osteopontin in tumor metastasis. J Surg Res 2004;121(2):228-41.

72. Curtis A, Wilkinson C. New depths in cell behaviour: reactions of cells to nanotopography. Biochem Soc Symp 1999;65:15-26.

73. Globus RK, Moursi A, Zimmerman D, Lull J, Damsky C. Integrin-extracellular matrix interactions in connective tissue remodeling and osteoblast differentiation. ASGSB Bull 1995;8(2):19-28.

74. Schneider GB, Zaharias R, Stanford C. Osteoblast integrin adhesion and signaling regulate mineralization. J Dent Res 2001;80(6):1540-4.

75. Dang Y, Zhang L, Song W, Chang B, Han T, Zhang Y, Zhao L. In vivo osseointegration of Ti implants with a strontium-containing nanotubular coating. Int J Nanomedicine 2016;11:1003-11.

76. Longo G, Ioannidu CA, Scotto d'Abusco A, Superti F, Misiano C, Zanoni R, Politi L, Mazzola L, Iosi F, Mura F and others. Improving Osteoblast Response In Vitro by a Nanostructured Thin Film with Titanium Carbide and Titanium Oxides Clustered around Graphitic Carbon. PLoS One 2016;11(3):e0152566.

77. Gittens RA, McLachlan T, Olivares-Navarrete R, Cai Y, Berner S, Tannenbaum R, Schwartz Z, Sandhage KH, Boyan BD. The effects of combined micron-/submicron-scale surface roughness and nanoscale features on cell proliferation and differentiation. Biomaterials 2011;32(13):3395-403.

78. Gehrke SA, Eliers Treichel TL, Pérez-Díaz L, Calvo-Guirado JL, Aramburú Júnior J, Mazón P, et al. Impact of Different Titanium Implant Thread Designs on Bone Healing: A Biomechanical and Histometric Study with an Animal Model. Journal of clinical medicine. 2019b Jun;8(6):777. doi:10.3390/jcm8060777.

79. Nevins M, Chu SJ, Jang W, Kim DM. Evaluation of an Innovative Hybrid Macrogeometry Dental Implant in Immediate Extraction Sockets: A Histomorphometric Pilot Study in Foxhound Dogs. Int J Periodontics Restorative Dent. 2019 Jan/Feb;39(1):29-37. doi: 10.11607/prd.3848.

80. Giannopoulou C, Cappuyns I, Mombelli A. Effect of smoking on gingival crevicular fluid cytokine profile during experimental gingivitis. J Clin Periodontol. 2003 Nov;30(11):996-1002.

81. Morozumi T, Kubota T, Sugita N, Itagaki M, Yoshie H. Alterations of gene expression in human neutrophils induced by smoking cessation. J Clin Periodontol 2004;31(12):1110-1116.

82. Prati AJ, Casati MZ, Ribeiro FV, Cirano FR, Pastore GP, Pimentel SP, Casarin RC. Release of bone markers in immediately loaded and nonloaded dental implants: a randomized clinical trial. J Dent Res.

2013 Dec;92(12 Suppl):161S-7S. doi: 10.1177/0022034513504951. Epub 2013 Oct 24. PMID: 24158337; PMCID: PMC3860065.

3 FIGURES AND TABLE LEGENDS

Table 1. Data concerning: sex, age, and implants distribution

Age (years)	43,94
Gender (female)	53,13
Ethnicity (White)	65,63
Cigarretes/day	16,03
Smoker time (years)	11
Implants distribution in Maxilla	34
Implants distribution in Mandibula	30

Figure 1. Schematic illustration DA and HCAN implants.

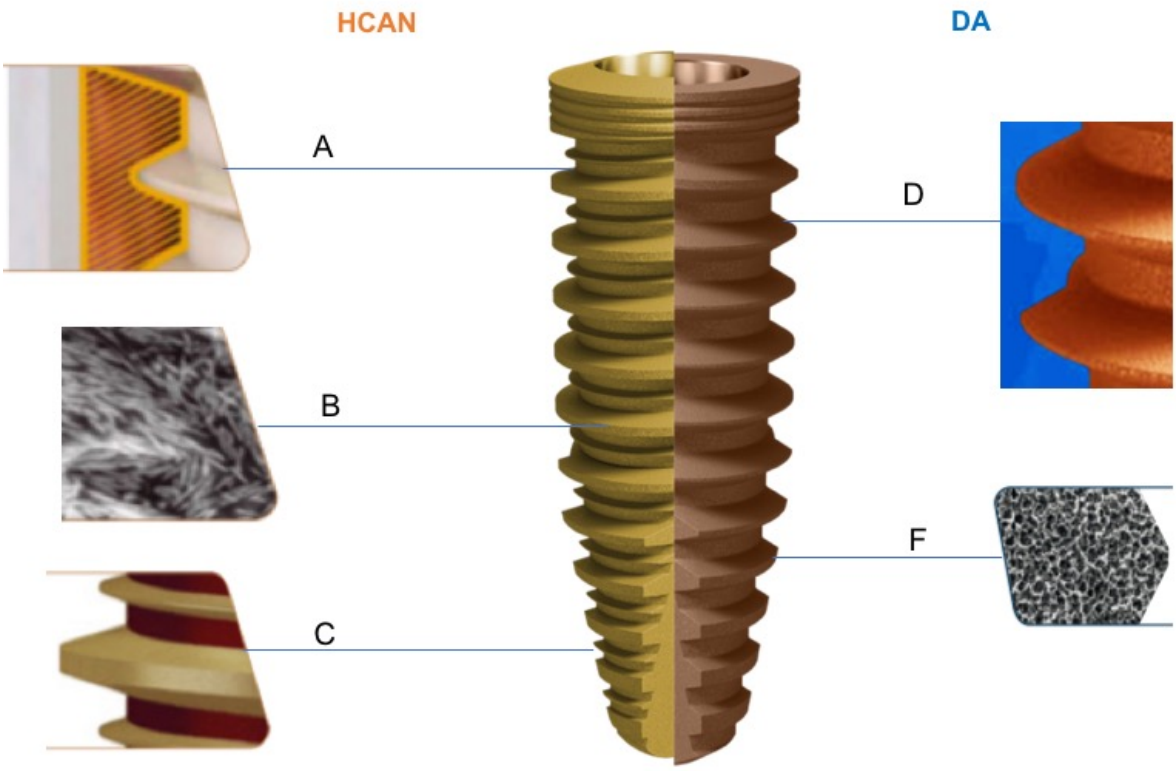

A – Healing Chambers; B – Hydroxyapatite Nanoactivated Surface; C – Hydrophilicity; D – Trapezoid and Ultra-Threadable Threads; F – Dual Acid Etech Surface

Figure 2. Flowchart of the study showing the patients enrolled in the pre-study phase and the selection of individuals for the study phase.

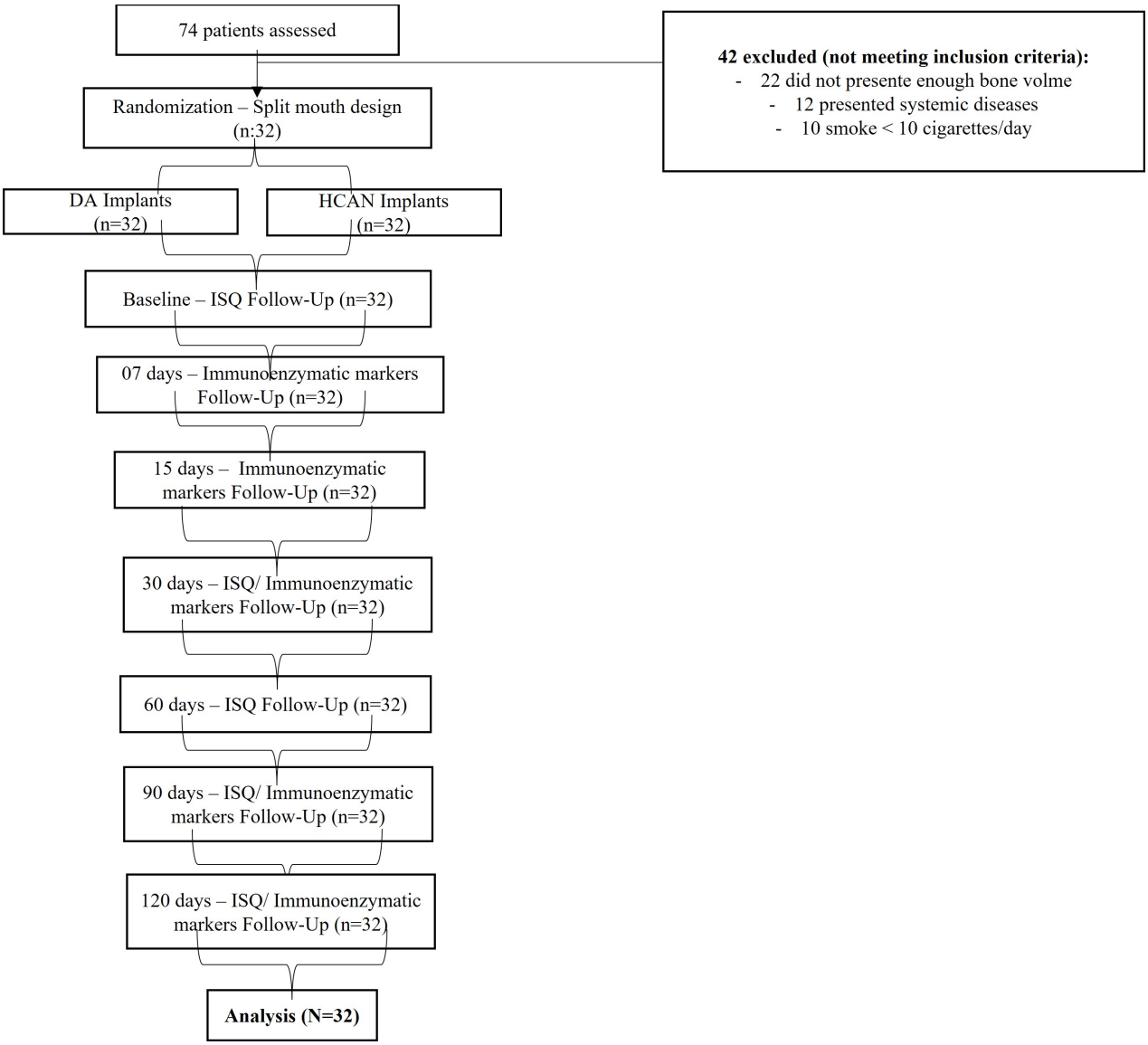

Figure 3. Graphic illustrating means and standard deviations of Implant stability quotient at baseline, 30, 60, 90 and 120 days.

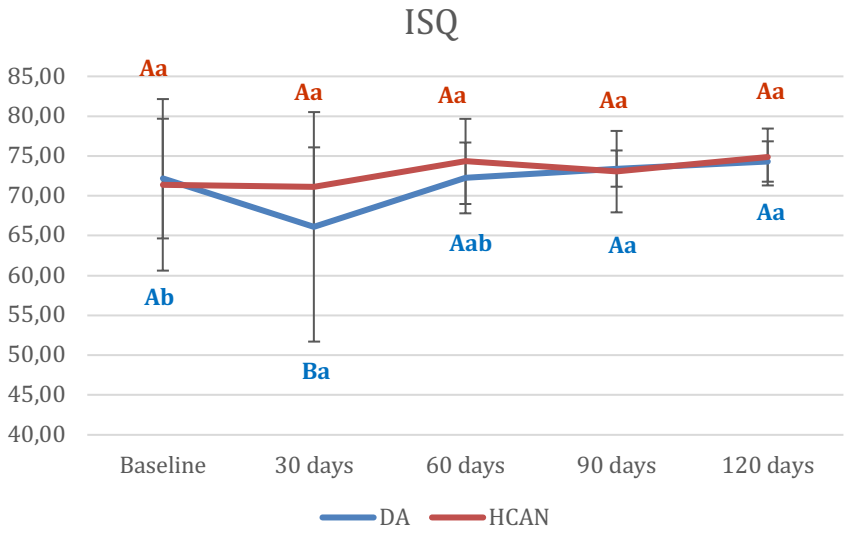

Different letters indicate statistical significance. Uppercase letter compares difference between groups (within same time; (Wilcoxon Test; $p<0.05$); Lowercase letters compare longitudinal data (within same group; Friedman test; $p<0.05$).

Figure 4. Levels of bone and angiogenic factors in the peri-implant fluid in the HCAN and DA groups.

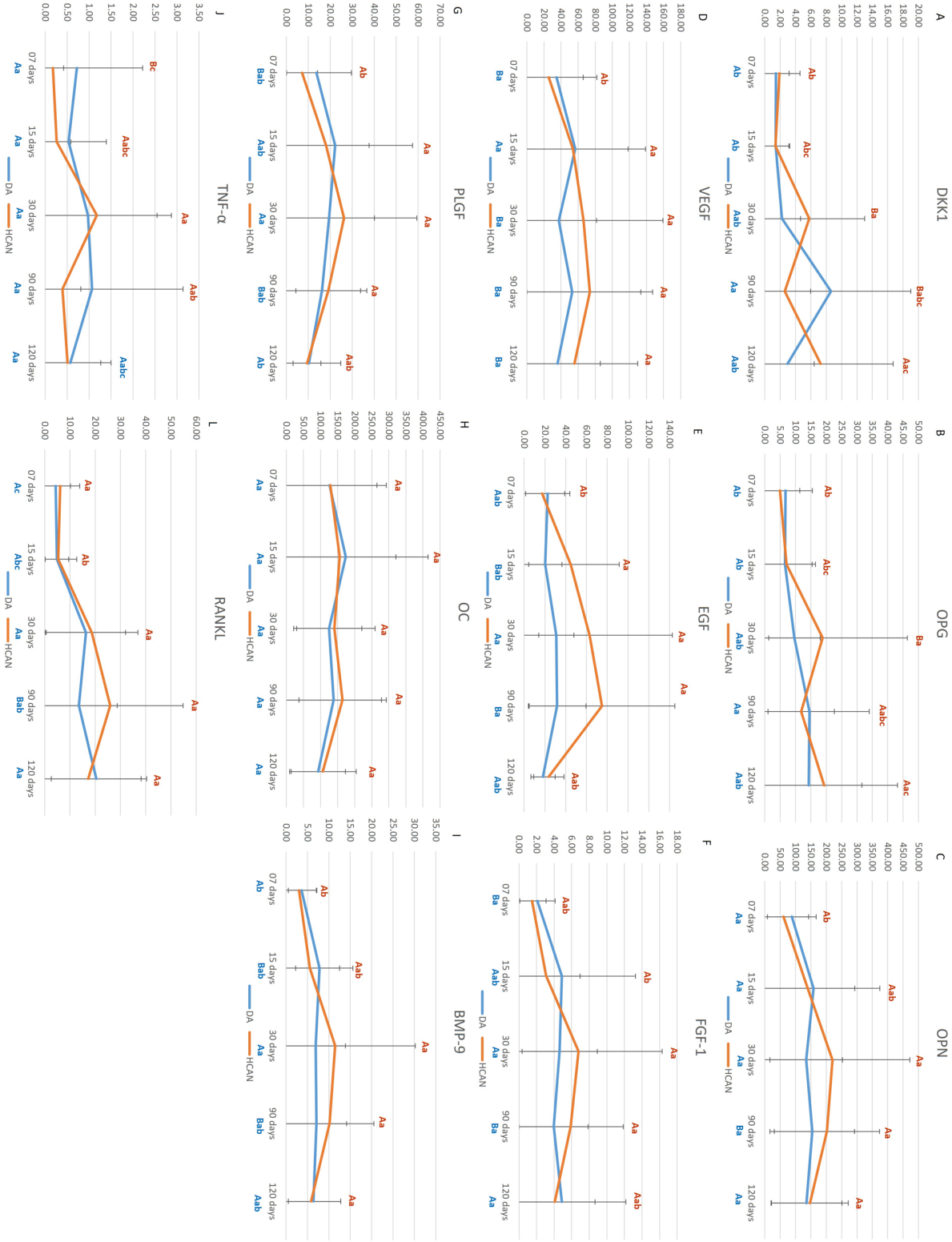

Different letters indicate statistical significance. Uppercase letter compares difference between groups (within same time; (Wilcoxon Test; $p<0.05$); Lowercase letters compare longitudinal data (within same group; Friedman test; $p<0.05$).

A- Dickkopf-1 (DKK1); B- Osteoprotegrin (OPG); C- Ostopontin (OPN); D- Vascular endothelial growth factor (VEGF); E- Epidermal growth factor (EGF); F- fibroblast growth factor (FGF); G- Placental growth factor (PlGF); H- Osteocalcin (OC); I- Bone morphogenetic protein-9 (BMP-9); J- Tumor necrosis factor (TNF) alpha; L- Receptor activator of nuclear factor-κB ligand (RANKL).

4 CONCLUSÃO GERAL

Os resultados do presente estudo mostraram que as modificações na macrogeometria e a superfície nanoativada melhoraram o reparo ósseo durante as fases iniciais da osteointegração, com maior estabilidade dos implantes, mesmo na presença dos efeitos negativos do tabagismo. Assim, as modificações na macrogeometria do implante associadas à superfície nanoativada modularam positivamente marcadores ósseos e angiogênicos, resultando em maior produção dos mesmos nas fases iniciais do reparo peri-implantar e melhoraram a estabilidade do implante em pacientes fumantes.

REFERÊNCIAS DA INTRODUÇÃO

1. Adam AB, O¨ zdamar MY, Esen HH, Gu¨nel E. Local effects of epidermal growth factor on the wound healing in esophageal anastomosis: an experimental study. Int J Pediatr Otorhinolaryngol 2017;99:8–12.

2. Adini A, Kornaga T, Firoozbakht F, Benja-min LE. Placental growth factor is a survival factor for tumor endothelial cells and macro-phages. Cancer Res 2002;62:2749–52.

3. Albrektsson T, Brånemark PI, Hansson HA, Lindström J. Osseointegrated titanium implants. Requirements for ensuring a long-lasting, direct bone-to-implant anchorage in man. Acta Orthop Scand. 1981;52(2):155-70. doi: 10.3109/17453678108991776. PMID: 7246093.

4. Albrektsson T, Wennerberg A. Oral implant surfaces: Part 1--review focusing on topographic and chemical properties of different surfaces and in vivo responses to them. Int J Prosthodont. 2004 Sep-Oct;17(5):536-43. PMID: 15543910.

5. Albrektsson T, Wennerberg A. Oral implant surfaces: Part 2--review focusing on clinical knowledge of different surfaces. Int J Prosthodont. 2004 Sep-Oct;17(5):544-64. PMID: 15543911.

6. Alsaadi G, Quirynen M, Komárek A, van Steenberghe D. Impact of local and systemic factors on the incidence of late oral implant loss. Clin Oral Implants Res. 2008 Jul;19(7):670-6. doi: 10.1111/j.1600-0501.2008.01534.x. Epub 2008 May 19. PMID: 18492080.

7. Alves JB, Ferreira CL, Martins AF, Silva GA, Alves GD, Paulino TP, Ciancaglini P, Thedei Jr G, Napimoga MH. Local delivery of EGF-liposome mediated bone modeling in orthodontic tooth movement by increasing RANKL expression. Life Sci 2009;4:693–9.

8. Babior BM. The respiratory burst oxidase. Hematol Oncol Clin N Am 1988;2:201–212.

9. Badenes-Catalán J, Pallarés-Sabater A. Influence of Smoking on Dental Implant Osseointegration: A Radiofrequency Analysis of 194 Implants. J Oral Implantol. 2021 Apr 1;47(2):110-117. doi: 10.1563/aaid-joi-D-19-00223. PMID: 32699886.

10. Belibasakis GN, Bostanci N. The RANKL-OPG system in clinical periodontology. J Clin Periodontol 2012; 39:239– 248.

11. Berglundh T, Abrahamsson I, Lang NP, Lindhe J. De novo alveolar bone formation adjacent to endosseous implants. *Clin Oral Implants Res* 2003;14:251-262.

12. Bluhm AC, Weistein J, Sonsa JA. Free radicals in tobacco smoke. Nature 1971;229:500.

13. Campos FE, Gomes JB, Marin C, et al. Effect of drilling dimension on implant placement torque and early osseointegration stages: An experimental study in dogs. *J Oral Maxillofac Surg* 2012, 70, e43–e50.

14. Campos JM, Prati AJ, Cirano FR, Pimentel SP, Pastore GP, Pecorari VG, Ribeiro FV, Casati MZ, Casarin RC. Smoking Modulates Gene Expression of Type I Collagen, Bone Sialoprotein, and Osteocalcin in Human Alveolar Bone. J Oral Maxillofac Surg 2015: 73: 2123-31. doi: 10.1016/j.joms.2015.06.168.

15. Chassanidis CG, Malizos KN, Varitimidis S, Samara S, Koromila T, Kollia P, Dailiana Z. Smoking affects mRNA expression of bone morphogenetic proteins in human periosteum. J Bone Joint Surg Br 2012: 94: 1427-32.

16. Chen H, Liu N, Xu X, Qu X, Lu E. Smoking, radiotherapy, diabetes and osteoporosis as risk factors for dental implant failure: a meta-analysis. PLoS One. 2013 Aug 5;8(8):e71955. doi: 10.1371/journal.pone.0071955. PMID: 23940794; PMCID: PMC3733795.

17. Chen H, Xu X, Liu M, et al. Sclerostin antibody treatment causes greater alveolar crest height and bone mass in an ovariectomized rat model of localized periodontitis. Bone 2015; 76: 141-148.

18. Chim SM, Tickner J, Chow ST, Kuek V, Guo B, Zhang G, Rosen V, Erber W, Xu J. Angiogenic factors in bone local environment. Cytokine Growth Factor Rev 2013;24:297–310.

19. Chrcanovic BR, Albrektsson T, Wennerberg A. Smoking and dental implants: A systematic review and meta-analysis. J Dent. 2015 May;43(5):487-98. doi: 10.1016/j.jdent.2015.03.003. Epub 2015 Mar 14. PMID: 25778741.

20. Coelho PG, Granjeiro JM, Romanos GE, Suzuki M, Silva NR, Cardaropoli G, Thompson VP, Lemons JE. Basic research methods and current trends of dental implant surfaces. J Biomed Mater Res B Appl Biomater 2009;88(2):579-96.

21. Coelho PG, Suzuki M, Guimaraes MVM, et al. Early bone healing around different implant bulk designs and surgical techniques: a study in dogs. *Clin Implant Dent Relat Res* 2010; 12:202–208.

22. Curtis A, Wilkinson C. New depths in cell behaviour: reactions of cells to nanotopography. Biochem Soc Symp 1999;65:15-26.

23. Dang Y, Zhang L, Song W, Chang B, Han T, Zhang Y, Zhao L. In vivo osseointegration of Ti implants with a strontium-containing nanotubular coating. Int J Nanomedicine 2016;11:1003-11.

24. Davies JE. Bone bonding at natural and biomaterial surfaces. Biomaterials. 2007 Dec;28(34):5058-67. doi: 10.1016/j.biomaterials.2007.07.049. Epub 2007 Aug 13. PMID: 17697711.

25. de Lange GL, Donath K. Interface between bone tissue and implants of solid hydroxyapatite or hydroxyapatite-coated titanium implants. Biomaterials 1989;10(2):121-5.

26. Freitas ACJ, Bonfante EA, Giro G et al. The effect of implant design on insertion torque and immediate micromotion. *Clin Oral Implants Res* 2012,23:113–118.

27. Gehrke SA, Eliers Treichel TL, et al. Impact of Different Titanium Implant Thread Animal Model. *J Clin Med* 2019; 31: 6.

28. Gehrke SA, Eliers Treichel TL, Pérez-Díaz L, Calvo-Guirado JL, Aramburú Júnior J, Mazón P, et al. Impact of Different Titanium Implant Thread Designs on Bone Healing: A Biomechanical and Histometric Study with an Animal Model. Journal of clinical medicine. 2019b Jun;8(6):777. doi:10.3390/jcm8060777.

29. Gehrke SA, Tumedei M, Aramburú Júnior J, et al. Histological and Histomorphometrical Evaluation of a New Implant Macrogeometry. A Sheep Study. *Int J Environ Res Public Health* 2020;17:3477.

30. Giannopoulou C, Cappuyns I, Mombelli A. Effect of smoking on gingival crevicular fluid cytokine profile during experimental gingivitis. J Clin Periodontol. 2003 Nov;30(11):996-1002.

31. Giorgetti AP, Cesar Neto JB, Ruiz KG, et al: Cigarette smoke inhalation modulates gene expression in sites of bone healing: A study in rats. Oral Surg Oral Med Oral Pathol Oral Radiol Endod 110:447, 2010

32. Gittens RA, McLachlan T, Olivares-Navarrete R, Cai Y, Berner S, Tannenbaum R, Schwartz Z, Sandhage KH, Boyan BD. The effects of combined micron-/submicron-scale surface roughness and nanoscale features on cell proliferation and differentiation. Biomaterials 2011;32(13):3395-403.

33. Gittens RA, McLachlan T, Olivares-Navarrete R, Cai Y, Berner S, Tannenbaum R, Schwartz Z, Sandhage KH, Boyan BD. The effects of combined micron-/submicron-scale surface roughness and nanoscale features on cell proliferation and differentiation. Biomaterials 2011;32(13):3395-403.

34. Globus RK, Moursi A, Zimmerman D, Lull J, Damsky C. Integrin-extracellular matrix interactions in connective tissue remodeling and osteoblast differentiation. ASGSB Bull 1995;8(2):19-28.

35. Heitz-Mayfield LJ. Peri-implant diseases: diagnosis and risk indicators. J Clin Periodontol. 2008 Sep;35(8 Suppl):292-304. doi: 10.1111/j.1600-051X.2008.01275.x. PMID: 18724857.

36. Ikar M, Grobecker-Karl T, Karl M, Steiner C. Mechanical stress during implant surgery and its effects on marginal bone: a literature review. *Quintessence Int* 2020;51:142-150.

37. Jimbo R, Tovar N, Anchieta RB, et al. The combined effects of undersized drilling and implant macrogeometry on bone healing around dental implants: an experimental study. *Int J Oral Maxillofac Surg* 2014;43:1269–1275.

38. Khang W, Feldman S, Hawley CE, Gunsolley J. A multi-center study comparing dual acid-etched and machined-surfaced implants in various bone qualities. J Periodontol. 2001 Oct;72(10):1384-90. doi: 10.1902/jop.2001.72.10.1384. PMID: 11699480.

39. Lappin Lappin DF, Sherrabeh S, Jenkins WM, Macpherson LM. Effect of smoking on serum RANKL and OPG in sex, age and clinically matched supportive-therapy periodontitis patients. J Clin Periodontol 2007:34: 271–277.

40. Lazzara RJ, Porter SS, Testori T, Galante J, Zetterqvist L. A prospective multicenter study evaluating loading of osseotite implants two months after placement: one-year results. J Esthet Dent. 1998;10(6):280-9. doi: 10.1111/j.1708-8240.1998.tb00505.x. PMID: 10321197.

41. Li R, Stewart DJ, von Schroeder HP, Mack- innon ES, SchemitschEH. Effect of cell-based VEGF gene therapy on healing of a segmental bone defect. J Orthop Res 2009;27:8–14.

42. Lioubavina-Hack N, Lang NP, Karring T. Significance of primary stability for osseointegration of dental implants. *Clin Oral Implants Res* 2006;17:244-250

43. Longo G, Ioannidu CA, Scotto d'Abusco A, Superti F, Misiano C, Zanoni R, Politi L, Mazzola L, Iosi F, Mura F and others. Improving Osteoblast Response In Vitro by a Nanostructured Thin Film with Titanium Carbide and Titanium Oxides Clustered around Graphitic Carbon. PLoS One 2016;11(3):e0152566.

44. Luginbuehl V, Meinel L, Merkle HP, Gander B. Localized delivery of growth factors for bone repair. Eur J Pharm Biopharm 2004;58:197–208.

45. Ma T, Tan MS, Yu JT, Tan L. Resveratrol as a Therapeutic Agent for Alzheimer's Disease. Biomed Res Int 2014: 2014: 350516. doi: 10.1155/2014/350516.

46. Marin C, Granato R, Suzuki M, Gil JN, JanalMN, Coelho PG. Histomorphologic and histomorphometric evaluation of various endosseous implant healing chamber configurations at early implantation times: a study in dogs. *Clin Oral Implants Res* 2010;21:577–583

47. McKee MD, Pedraza CE, Kaartinen MT. Osteopontin and wound healing in bone. Cells Tissues Organs 2011; 194:313– 319.

48. Mensah KA, Li J, Schwarz EM. The emerging field of osteoimmunology. Immunol Res 2009: 45: 100-13. doi: 10.1007/s12026-009-8093-x.

49. Monje A, Ravidà A, Wang HL, Helms JA, Brunski JB. Relationship Between Primary/Mechanical and Secondary/Biological Implant Stability. *Int J Oral Maxillofac Implants* 2019;34:s7-s23.

50. Montero A, Okada Y, Tomita M, Ito M, Tsurukami H, Nakamura T, Doetschman T, Coffin JD, Hurley MM. Disruption of the fibroblast growth factor-2 gene results in decreased bone mass and bone formation. J Clin Invest 2000;105:1085–93.

51. Moraschini V, Barboza Ed. Success of dental implants in smokers and non-smokers: a systematic review and meta-analysis. Int J Oral Maxillofac Surg. 2016 Feb;45(2):205-15. doi: 10.1016/j.ijom.2015.08.996. Epub 2015 Sep 15. PMID: 26385308.

52. Morozumi T, Kubota T, Sugita N, Itagaki M, Yoshie H. Alterations of gene expression in human neutrophils induced by smoking cessation. J Clin Periodontol 2004;31(12):1110-1116.

53. Negri BM, Pimentel SP, Casati MZ, Cirano FR, Casarin RC, Ribeiro FV. Impact of a chronic smoking habit on the osteo-immunoinflammatory mediators in the peri-implant fluid of clinically healthy dental implants. Arch Oral Biol. 2016 Oct;70:55-61. doi: 10.1016/j.archoralbio.2016.05.014. Epub 2016 Jun 7. PMID: 27328151.

54. Nevins M, Chu SJ, Jang W, Kim DM. Evaluation of an Innovative Hybrid Macrogeometry Dental Implant in Immediate Extraction Sockets: A Histomorphometric Pilot Study in Foxhound Dogs. Int J Periodontics Restorative Dent. 2019 Jan/Feb;39(1):29-37. doi: 10.11607/prd.3848.

55. Óbice ALS, Correa MG, Feng HS, Ribeiro FV, Cirano FR, Casati MZ, Pimentel SP. The impact of implant abutment surface treatment with TiO2 on peri-implant levels of angiogenesis and bone-related markers: a randomized clinical trial. Int J Oral Maxillofac Surg. 2019 Jul;48(7):962-970. doi: 10.1016/j.ijom.2018.12.012. Epub 2019 Jan 17. PMID: 30661944.

56. Peng Y, Kang Q, Cheng H, Li X, Sun MH, Jiang W, Luu HH, Luo J, Szatkowski JP, Vanichakarn P, Park JY, Li Y, Haydon RC, He TC. Transcriptional characterization of bone morphogenetic proteins (BMPs)-medi-ated osteogenic signaling. J Cell Biochem 2003;90:1149–65.

57. Peng Y, Kang Q, Luo Q, Jiang W, Si W, Liu BA, Luu HH, Park JK, Li X, Luo J, Montag AG, Haydon RC, He TC. Inhibitor of DNA binding/differentiation helix-loop-helix proteins mediate bone morphogenetic proteininduced osteoblast differentiation of mesenchymal stem cells. J Biol Chem 2004;279:32941–9.

58. Pimentel SP, Shiota R, Cirano FR, Casarin RCV, Pecorari VGA, Casati MZ, Haas AN, Ribeiro FV. Occurrence of peri-implant diseases and risk indicators at the patient and implant levels: A multilevel cross-sectional study. J Periodontol. 2018 Sep;89(9):1091-1100.

59. Prati AJ, Casati MZ, Ribeiro FV, Cirano FR, Pastore GP, Pimentel SP, Casarin RC. Release of bone markers in immediately loaded and nonloaded dental implants: a randomized clinical trial. J Dent Res. 2013 Dec;92(12 Suppl):161S-7S. doi: 10.1177/0022034513504951. Epub 2013 Oct 24. PMID: 24158337; PMCID: PMC3860065.

60. Pryor WA. Biological effects of cigarette smoke, wood smoke and the smoke from plastics: the use of electron spin resonance. Free Rad Biol Med 1992;13:659–676.

61. Puleo DA, Nanci A. Understanding and controlling the bone-implant interface. Biomaterials. 1999 Dec;20(23-24):2311-21. doi: 10.1016/s0142-9612(99)00160-x. PMID: 10614937.

62. Qian J, Wennerberg A, Albrektsson T. Reasons for marginal bone loss around oral implants. Clin Implant Dent Relat Res. 2012 Dec;14(6):792-807. doi: 10.1111/cid.12014. Epub 2012 Nov 30. PMID: 23198697.

63. Renvert S, Quirynen M. Risk indicators for peri-implantitis. A narrative review. Clin Oral Implants Res. 2015 Sep;26 Suppl 11:15-44. doi: 10.1111/clr.12636. PMID: 26385619.

64. Ribeiro FV, Pimentel SP, Corrêa MG, Bortoli JP, Messora MR, Casati MZ. Resveratrol reverses the negative effect of smoking on peri-implant repair in the tibia of rats. Clin Oral Implants Res. 2019 Jan;30(1):1-10. doi: 10.1111/clr.13384. Epub 2018 Dec 26. PMID: 30402971.

65. Sato Y, Shimada T, Takaki R. Autocrinological role of basic fibroblast growth factor on tube formation of vascular endothelial cells in vitro. Biochem Biophys Res Commun 1991;180:1098–102.

66. Schneider GB, Zaharias R, Stanford C. Osteoblast integrin adhesion and signaling regulate mineralization. J Dent Res 2001;80(6):1540-4.

67. Sezer O, Niemo¨ ller K, Jakob C, Zavrski I, Heider U, Eucker J, Kaufmann O, Possinger K. Relationship between bone marrow angiogenesis and plasma cell infiltration and serum beta2-microglobulin levels in patients with multiple myeloma. Ann Hematol 2001;80:598–601.

68. Shibli JA, Feres M, de Figueiredo LC, Iezzi G, Piattelli A. Histological comparison of bone to implant contact in two types of dental implant surfaces: a single case study. J Contemp Dent Pract. 2007 Mar 1;8(3):29-36. PMID: 17351679.

69. Shibli JA, Grassi S, de Figueiredo LC, Feres M, Marcantonio E Jr, Iezzi G, Piattelli A. Influence of implant surface topography on early osseointegration: a histological study in human jaws. J Biomed Mater Res B Appl Biomater. 2007 Feb;80(2):377-85. doi: 10.1002/jbm.b.30608. PMID: 16850464.

70. Shibli JA, Grassi S, Piattelli A, Pecora GE, Ferrari DS, Onuma T, d'Avila S, Coelho PG, Barros R, Iezzi G. Histomorphometric evaluation of bioceramic molecular impregnated and dual acid-etched implant surfaces in the human posterior maxilla. Clin Implant Dent Relat Res. 2010 Dec;12(4):281-8. doi: 10.1111/j.1708-8208.2009.00174.x. PMID: 19438956.

71. Strietzel FP, Reichart PA, Kale A, Kulkarni M, Wegner B, Küchler I. Smoking interferes with the prognosis of dental implant treatment: a systematic review and meta-analysis. J Clin Periodontol. 2007 Jun;34(6):523-44. doi: 10.1111/j.1600-051X.2007.01083.x. PMID: 17509093.

72. Sun C, Zhao J, Jianghao C, Hong T. Effect of Heavy Smoking on Dental Implants Placed in Male Patients Posterior Mandibles: A Prospective Clinical Study. J Oral Implantol. 2016 Dec;42(6):477-483. doi: 10.1563/aaid-joi-D-16-00078. Epub 2016 Aug 19. PMID: 27541691.

73. Twito D, Sade P. The effect of cigarette smoking habits on the outcome of dental implant treatment. PeerJ. 2014 Sep 2;2:e546. doi: 10.7717/peerj.546. PMID: 25237600; PMCID: PMC4157230.

74. Udagawa N, Takahashi N, Yasuda H, Mizuno A, Itoh K, Ueno Y, Shinki T, Gillespie MT, Martin TJ, Higashio K, Suda T. Osteoprotegerin produced by osteoblasts is an important regulator in osteoclast devel- opment and function. Endocrinology 2000;141:3478–84.

75. van Steenberghe D, Jacobs R, Desnyder M, Maffei G, Quirynen M. The relative impact of local and endogenous patient-related factors on implant failure up to the abutment stage. Clin Oral Implants Res. 2002 Dec;13(6):617-22. doi: 10.1034/j.1600-0501.2002.130607.x. PMID: 12519336.

76. Verrastro Neto A, Andrade R, Corrêa MG, Casarin RCV, Casati MZ, Pimentel SP, Ribeiro FV, Cirano FR. The impact of different torques for the insertion of immediately loaded implants on the peri-implant levels of angiogenesis- and bone-related markers. Int J Oral Maxillofac Surg. 2018 May;47(5):651-657. doi: 10.1016/j.ijom.2017.11.001. Epub 2017 Nov 23. PMID: 29173997.

77. Vestergaard P, Mosekilde L: Fracture risk associated with smoking: A meta-analysis. J Intern Med 254:572, 2003

78. Wai PY, Kuo PC. The role of Osteopontin in tumor metastasis. J Surg Res 2004;121(2):228-41.

79. Wang D, Li SP, Fu JS, Bai L, Guo L. Resveratrol augments therapeutic efficiency of mouse bone marrow mesenchymal stem cell-based therapy in experimental autoimmune encephalomyelitis. Int J Dev Neurosci 2016; 49:, 60-66.

80. Xiao GG, Wang M, Li N, Loo JA, Nel AE. Use of proteomics to demonstrate a hierarchical oxidative stress response to diesel exhaust particle chemicals in a macrophage cell line. J Biol Chem 2003: 278: 50781-90.

81. Yamano S, Berley JA, Kuo WP, Gallucci GO, Weber HP, Sukotjo C. Effects of nicotine on gene expression and osseointegration in rats. Clin Oral Implants Res 2010: 21: 1353-9. doi: 10.1111/j.1600-0501.2010.01955.x.

82. Yildiz D. Nicotine, its metabolism and an overview of its biological effects. Toxicon. 2004 May;43(6):619-32. doi: 10.1016/j.toxicon.2004.01.017. PMID: 15109883.