

---

# Assessment of maxillary bone density by the tomodensitometric scale in Cone-Beam Computed Tomography (CBCT)

*Avaliação da densidade óssea dos maxilares por meio de escala tomodensitométrica em Tomografia Computadorizada de Feixe Cônico (TCFC)*

Silvana Maria Felicori<sup>1</sup>, Renata de Saldanha da Gama<sup>2</sup>, Celso Silva Queiroz<sup>3</sup>, Daniela Miranda Richarte de Andrade Salgado<sup>2</sup>, Jéssica Rabelo Mina Zambrana<sup>2</sup>, Élcio Magdalena Giovani<sup>1</sup>, Claudio Costa<sup>2</sup>

<sup>1</sup>Post Graduation Program, Dentistry School, Universidade Paulista, São Paulo-SP, Brazil; <sup>2</sup>Post Graduation Program, Oral Diagnosis, Universidade de São Paulo, São Paulo-SP, Brazil; <sup>3</sup>Dentistry School, Universidade Estadual do Rio de Janeiro, Rio de Janeiro-RJ, Brazil.

---

## Abstract

**Objective** – To analyze bone density in images of the anterior and posterior regions of the mandible and maxilla obtained with Cone-Beam Computed Tomography. Planning of surgeries for implant placement requires information about bone density, which is directly related to stability. **Methods** – This retrospective study included female (25) and male (25) patients (50) with ages in the range 30-40/45 years. Images of their exams (200 transaxial slices; 2-mm thick) were analyzed in the anterior (50) and posterior (50) regions of the mandible and anterior (50) and posterior (50) regions of the maxilla using the bone density tool of the Xoran (i-CAT<sup>®</sup>) software. Our data were compared and correlated with computed tomography data obtained in the literature. **Results** – Mean gray values were utilized to determine the density values for the anterior mandible (562.2, 3.3) and maxilla (531.3, 2.8) and the posterior mandible (503.8, 3.0) and maxilla (394.5, 2.9). The results were statistically analyzed for correlation between our findings and those of the literature. The *t* test was utilized to obtain additional information related to gender; and the Pearson correlation analysis was utilized to assess the differences between observers 1 and 2. **Conclusions** – Statistically significant differences ( $p > 0.05$ ) between densities in the anterior and posterior regions were not found, and our values were consistent with those in the literature obtained with Computed Tomography.

**Descriptors:** Cone-Beam computed tomography; Tomography, X-Ray computed; Tomography; Bone density

## Resumo

**Objetivo** – Analisar a densidade óssea nas regiões anterior e posterior dos maxilares em imagens obtidas por meio de Tomografia Computadorizada de Feixe Cônico. O planejamento de cirurgias requer informações sobre a densidade óssea da região escolhida para instalação de implantes. **Métodos** – Este estudo retrospectivo incluiu 50 pacientes, sendo 25 do gênero feminino e 25 masculino com idades na faixa 30-40/45 anos. As imagens de seus exames (200 cortes transaxiais com espessura de 2 mm) foram analisadas nas regiões anterior (50) e posterior (50) da mandíbula e anterior (50) e posterior (50) da maxila usando a ferramenta de densidade óssea do software Xoran (tomógrafo i-CAT<sup>®</sup>). Os nossos dados foram comparados e correlacionados com aqueles de tomografia computadorizada obtidos na literatura. **Resultados** – Valores médios de cinza foram usados para determinar os valores de densidade para mandíbula (562,2; 3,3) e maxila (531,3; 2,8) anteriores, e mandíbula (503,8; 3,0) e maxila (394,5; 2,9) posteriores. Os resultados foram submetidos à análise estatística para comparação entre os achados deste estudo e aqueles da literatura. O teste *t* foi usado para obter informações adicionais relacionadas aos gêneros; e a análise de correlação de Pearson foi usada para avaliar a diferença entre os observadores 1 e 2. **Conclusões** – Diferenças estatisticamente significantes ( $p < 0,05$ ) entre as densidades nas regiões anterior e posterior não foram encontradas, e os valores que nós obtivemos com Tomografia Computadorizada de Feixe Cônico foram compatíveis com aqueles da literatura com Tomografia Computadorizada.

**Descritores:** Tomografia computadorizada de feixe cônico; Tomografia computadorizada por Raios X; Tomografia; Densidade óssea

---

## Introduction

The success or failure in dental implants is related to assessment before the surgery. The area chosen for the implant should be analyzed taking into account its relationship with the surrounding anatomical structures, in addition to height, bone structure and density in that region<sup>1</sup>. Several researchers agree that a good preoperative assessment of bone density may guide the surgeon's decision on patient selection, surface of the implant, and surgical technique to be used<sup>2</sup>.

In Dentistry, planning-related anatomical studies necessarily involve the use of imaging exams including CT scans. After the computed tomography (CT) technique was introduced, an increase was observed in the quality of the images and therefore in details of anatomi-

cal structures. Computer software allow quantitative and qualitative assessment of bone tissue<sup>3</sup>.

In CT, the tomodensitometric scale for bone density values is expressed in Hounsfield units (HU). In cone-beam CT (CBCT), bone quality can be assessed by gray tones obtained from voxels contained in a given region of interest (ROI). These gray values represent the X-ray beam attenuation as caused by the tissues, and they allow us to assess the mineralization degree in a given area<sup>3</sup>.

A range of values for bone density can be used to describe the maxilla and mandible in TC images: high-density cortical bone (>600 HU), dense cortical bone (400-600 HU), and low-density cortical bone (<200 UH)<sup>4</sup>.

Recently, Razi, Niknami, and Ghazani<sup>5</sup> (2014) studied experimental animals and observed a strong correlation between gray scales (CBCT) and UH (CT). As the grays-

cale CBCT is the criterion for measuring bone density in the pre-surgical evaluation in implantology, the authors recommend the use of that scale instead of UH as obtained in TC.

Thus, comparison between gray scale values (CBCT) and those of studies in UH (CT) in the maxilla and mandible regions is necessary.

## Methods

The project of this study was approved by the local Ethics Committee (Universidade Paulista, UNIP; protocol: 291/10CEP/ICS/UNIP).

Fifty fully edentulous subjects (females: 25; males: 25) were examined using a TC (i-CAT®; Imaging Sciences, Hatfield, PA, USA) equipment in the period 01 Aug-30 Nov 2010, and 200 transaxial CT slices (image file of the Clínica de Radiologia IsoOrthographic, São Paulo, SP, Brazil) were analyzed. The XoranConnect® (Xoran Technologies, LLC, Ann Arbor, MI, USA) software was used to read the gray tones (Figure 1). The CT slices were obtained using the following parameters: peak voltage 120 kV; axial section thickness: 0.3 mm; transaxial section thickness: 2 mm; reading magnification of the image: 200%; standard measurement area: 6.28 mm<sup>2</sup>; and voxel size: 0.2 mm.

Only gender of the subjects and their age at the time of CT examination were used to identify the images. In the selection of both male and female subjects, the age of 40/45 years (at the time of radiographic examination) was established as the upper limit to avoid variation in bone density due to a reduction in bone mineral mass (osteoporosis) which occurs from the fifth decade on.

The image data were extracted by two experienced radiologists, and their readings were previously standardized. These data were compared with those from the literature, in which CT was used. All data were then distributed into six groups, according to the technology and source: G1 (present study – CBCT), G2 (TC; Norton and Gamble<sup>6</sup> (2001)), G3 (TC; Shapurian *et al.*<sup>7</sup> (2006)), G4 (TC; Turkiylmaz *et al.*<sup>8</sup> (2007)), G5 (CT; Turkiylmaz *et al.*<sup>9</sup> (2008)) and G6 (CT; Fuh *et al.*<sup>10</sup> (2010)).

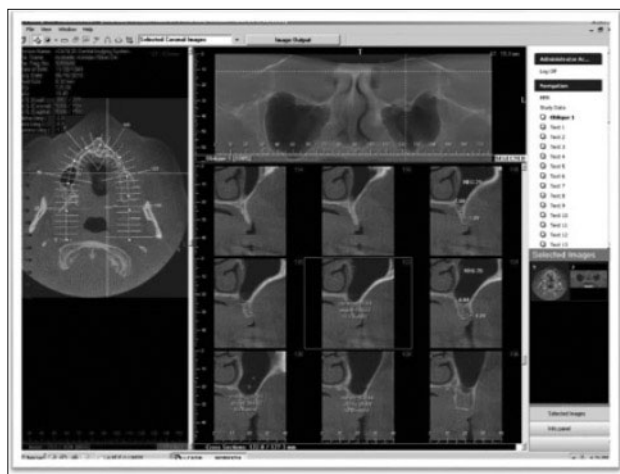


Figure 1. Image of the software screen (Xoran CT) used to measure bone density in the maxilla and mandible

## Results

The results of this study are presented as tables and figure, which show the distribution of the sample according to the anatomical region, gender, and examiner.

Two hundred potential implant sites were used in this study. The images (CBCT i-CAT® system) were obtained from 50 patients (25 men and 25 women) aged in the range 30-40/45, who were referred to the clinic for evaluation before surgery.

The results of this study on the different anatomical regions of the maxilla and mandible are shown in Table 1 and Figure 1. The values found in this study decrease from the anterior to the posterior regions as follows: anterior mandible ( $562.2 \pm 3.3$ ); anterior maxilla ( $531.3 \pm 2.8$ ); posterior mandible ( $503.8 \pm 3.0$ ); posterior maxilla ( $394.5 \pm 2.9$ ). The highest values for bone density were found in the anterior mandible, followed by the anterior maxillary, posterior mandible, and posterior maxilla. The bone density values are shown as grayscale (CBCT) and HU (CT), according to the technology: G1; G2; G3; G4; G5 and G6.

Group 1 was compared to other groups, and statistical difference was detected in the following anatomical regions: G1xG2: anterior mandible ( $p < 0.005$ ); G1xG3: posterior mandible; G1xG4: anterior maxilla and mandible; G1xG5: anterior maxilla and mandible; and G1xG6: none (Table 1).

A high correlation ( $r=0.1$ ) was found between Group 1 and Groups 2, 3, 4, 5, and 6, and the closest values in relation to  $r=0.01$  were found in the following comparisons: G1xG2, G1xG4, and G1xG5 ( $r=0.9$ ). An inferior correlation was observed in the comparison between G1xG3 and G1xG6 ( $r=0.8$ ). In comparison between the groups who used CT, a high correlation was observed between G2xG4, G2xG5, and G3xG6 ( $r=0.9$ ), and a lower correlation was observed between G2xG3, G3xG4, G3xG5, G4xG6, and G5xG6 (Table 1).

The statistical analysis did not indicate statistically significant differences between observers 1 and 2. In addition, statistically significant differences were not observed between males and females in the given age group (Table 2).

## Discussion

Primary stability of the implant depends on bone density and quality. Therefore, these characteristics must be known<sup>4,9-11</sup>. Methods for assessment of bone density were proposed by Lekholm and Zarb (cited Oliveira *et al.*<sup>12</sup>) using pantomographic images and the measure of the operator's pressure required to drill the bone. Lekholm and Zarb (cited in Oliveira *et al.*<sup>12</sup>) classified bone density into four groups according to the cortical and trabecular bone: Group 1: dense bone with little trabecular bone; Group 2: bone matrix surrounded by a dense cortical; Group 3: large amount of bone matrix surrounded by a thin cortical; and Group 4: cancellous bone<sup>10</sup>. Many authors agree that prior knowledge about the nature of bone and its constitution are important to predict the implant lifetime and thus success of treatment<sup>4,9,11</sup>.

**Table 1. Comparison between the mean values for bone density in each region analyzed in this study and studies by other authors**

Anatomical Regions	Anatomical Regions					
	G1	G2	G3	G4	G5	G6
Anterior Maxilla	531.3	696.1	517	715.8*	721*	516
Posterior Maxilla	364.5	417.3	330	455.1	505	332
Anterior Mandible	562.2	970*	559	944.9*	927*	530
Posterior Mandible	503.8	669.6*	321*	674.3	708*	359

**Table 2. Mean values and their standard deviations (SD) for bone density in both genders (total)**

Anatomical Regions	Mean values	SD
Anterior Maxilla	531.32	2.77
Posterior Maxilla	394.49	2.8
Anterior Mandible	562.22	2.81
Posterior Mandible	503.8	2.82

Statistically significant differences between the mean values (ANOVA; Tukey's test;  $p > 0.05$ ) were not observed

The CT opened a new horizon to imaging diagnosis when it allowed not only a linear (panoramic radiography) but in depth view, in the width, height, and depth planes (bucolingual; sections with 1-2 mm thick). By using a specific software, the Hounsfield (HU) tomodensitometric scale is applied to three-dimensional images obtained by the CT technique. Applying this scale allows to obtain bone density values from the tissue attenuation coefficient (graduation of the gray levels in the radiographic image). However, the values in this scale may vary depending on the type of equipment used and software applied to the image<sup>7</sup>.

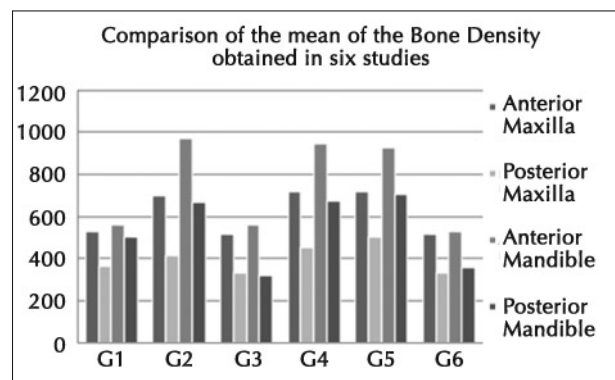
As compared with CT, CBCT provides the patient with lower cost<sup>9</sup> and radiation dose, and a high correlation between values for CBCT and CT, although the methods for primary acquisition<sup>3</sup> and high image resolution are different<sup>13</sup>. Both technologies provide objective measures<sup>14</sup> and reliable images<sup>15</sup>, favoring the use of CBCT to assess bone structure in the maxillomandibular complex.

The present study allowed us to relate the CBCT findings with those of five studies in which CT was used in the tomodensitometric analysis of the anterior and posterior regions of the maxilla and mandible.

Norton and Gamble<sup>6</sup> (2001), Turkyilmaz, Tözüm and Tumer<sup>8</sup> (2007), Turkyilmaz *et al.*<sup>9</sup> (2008) showed average values above those found in our study (Table 1). However, agreement between the values was observed in each of the four regions. The values in the four regions showed to be decreasing: the anterior mandible showed the highest values for bone density, which were followed by those for the anterior maxilla, posterior mandible, and posterior maxilla. Such order is in agreement with that found in the literature and used in this study<sup>4,6,8-9,11,16</sup>.

The mean values found in this study were closer to those published by Shapurian *et al.*<sup>7</sup> (2006) and Fuh *et al.*<sup>10</sup> (2010) (Table 1). The values found by Turkyilmaz, Tözüm and Tumer<sup>8</sup> (2007), Turkyilmaz *et al.*<sup>9</sup> (2008), Turkyilmaz *et al.*<sup>17</sup> (2007) were higher because they may have considered those of the cortical bone, which are higher than those in the trabecular bone<sup>10</sup>.

Comparing our mean values of bone density for each region analyzed and those of other authors, the highest mean values were obtained in two studies by Turkyilmaz, Tözüm and Tumer<sup>8</sup> (2007), Turkyilmaz *et al.*<sup>9</sup> (2008) and the lowest mean values were obtained by Shapurian *et al.*<sup>7</sup> (2006) and Fuh *et al.*<sup>10</sup> (2010) (Table 1 and Graphic 1).



**Graphic 1. Mean values of bone density in different anatomical regions obtained in different studies**

Statistical analysis (ANOVA; Tukey's test;  $p < 0.05$ ) showed a significant difference between the mean values for bone density obtained in this study for the anterior mandible: Norton and Gamble<sup>6</sup> (2001) (970,0); Turkyilmaz, Tözüm and Tumer<sup>8</sup> (2007) (944,9) e Turkyilmaz *et al.*<sup>9</sup> (2009) (927,0). Anterior maxilla: Turkyilmaz, Tözüm and Tumer<sup>8</sup> (2007) 715,8) e Turkyilmaz *et al.*<sup>9</sup> (2009) (708,0). Posterior mandible: Norton, Gamble<sup>6</sup> (970,0), Turkyilmaz, Tözüm and Tumer<sup>8</sup> (2007) (674,3), e Turkyilmaz *et al.*<sup>9</sup> (2009) (721,0). Posterior maxilla: Shapurian *et al.*<sup>7</sup> (2006) (321,0) e Turkyilmaz *et al.*<sup>9</sup> (2009) (505,0) (Table 1 and Graphic 1).

A strong correlation ( $r=0.1$ ) was found between the mean values for bone density obtained in this study (CBCT) and those of five groups who worked with TC.

Regarding gender, statistically significant differences were not found between mean values for bone density (ANOVA; Tukey's test;  $p < 0.05$ ), and our values coincided were equal to those presented by Shapurian *et al.*<sup>7</sup> (2006).

With regard to interpretation of data by examiners 1 and 2, no statistically significant difference (Pearson correlation,  $r$ ) was found between them. Therefore, their readings of bone density in CBCT can be considered reliable. This finding is in agreement with that of Loubele *et al.*<sup>16</sup> (2007), who also found no statistically significant difference between examiners readings.

Therefore, as recently stated by Razi, Niknami, and Ghazani<sup>5</sup> (2014), we conclude that CBCT is an appropriate tool to assess bone density in planning integrated bone implant.

Further studies should be conducted to confirm linearity of bone density measurements in CT and CBCT taking into account different interference factors, such as equipment for imaginologic examination, reading programs, and working conditions (kilovoltage, milliamperage current, and exposure time).

## Conclusion

Cone-Beam Computed Tomography is a useful technique in planning implants. Tomodensitometric analysis showed to be useful to assess bone quality in the implant area, although isolated use of this tomodensitometric scale should be avoided. Further studies should be conducted to identify possible interference factors.

## References

1. Frederiksen NL. Diagnostic imaging in dental implantology. *Oral Surg Oral Med Oral Pathol Oral Radiol Endod.* 1995; Nov; 80(5):540-54.
2. Shahlaie M, Gantes B, Schulz E, Riggs M, Crigger M. Bone density assessments of dental implant sites: 1. Quantitative Computer Tomography. *Int J Oral Maxillofac Implants.* 2003; 18(2):224-31.
3. Valiyaparambil JV, Yamany I, Ortiz D, Shafer DM, Pendrys D, Freilich M, *et al.* Bone quality evaluation: comparison of cone beam computed tomography and subjective surgical assessment. *Int J Oral Maxillofac Implants.* 2012; Sep-Oct; 27(5):1271-7.
4. Aranyarachkul P, Caruso J, Gantes B, Schultz E, Riggs M, Dus I, *et al.* Bone density assessment of dental implant sites: 2. Quantitative Cone-Beam Computadorized Tomography. *Int J Oral Maxillofac Implants.* 2005; May-Jun; 20(3):416-24.
5. Razi T, Niknami M, Alavi Ghazani F. Relationship between Hounsfield Unit in CT Scan and Gray Scale in CBCT. *J Dent Res Dent Clin Dent Prospects.* 2014; Spring; 8(2):107-10.
6. Norton MR, Gamble C. Bone classification: an objective scale of density using the computerized tomography scan. *Clin Oral Implants Res.* 2001; Feb; 12(1):79-84.
7. Shapurian T, Damoulis PD, Reiser GM, Griffin TJ, Rand WM. Quantitative evaluation of bone density using the Hounsfield Index. *Int J Oral Maxillofac Implants.* 2006; Mar-Apr; 21(2):290-7.
8. Turkyilmaz I, Tözüm TF, Tumer C. Bone density assessments of oral implant sites using computerized tomography. *J Oral Rehabil.* 2007; Apr; 34(4):267-72.
9. Turkyilmaz I, Ozan O, Yilmaz B, Ersoy AE. Determination of bone quality of 372 implant recipient sites using Hounsfield unit from computerized tomography: a clinical study. *Clin Implant Dent Relat Res.* 2008; Dec; 10(4):238-44.
10. Fuh LJ, Huang HL, Chen CS, Fu KL, Shen YW, Tu MG, *et al.* Variations in bone density at dental implant sites in different regions of the jawbone. *J Oral Rehabil.* 2010; May 1; 37(5):346-51.
11. Ikumi N, Tsutsumi S. Assessment of correlation between computerized tomography values of the bone and cutting torque values at implant placement: a clinical study. *Int J Oral Maxillofac Implants.* 2005; Mar-Apr; 20(2):253-60.
12. Oliveira RC, Leles CR, Normanha LM, Lindh C, Ribeiro-Rotta RF. Assessment of trabecular bone density at implant sites on CT images. *Oral Surg Oral Med Oral Pathol Oral Radiol Endod.* 2008; Feb; 105(2):231-8.
13. Turkyilmaz I, Sennerby L, McGlumphy EA, Tözüm TF. Biomechanical aspects of primary implant stability: a human cadaver study. *Clin Implant Dent Relat Res.* 2009; Jun; 11(2):113-9.
14. Liang X, Jacobs R, Hassan B, Li L, Pauwels R, Corpas L, *et al.* A comparative evaluation of Cone Beam Computed Tomography (CBCT) and Multi-Slice CT (MSCT). Part 1. On subjective image quality. *Eur J Radiol.* 2010; Aug; 75(2):265-9.
15. Lee S, Gantes B, Riggs M, Crigger M. Bone density assessments of dental implant sites: 3. bone quality evaluation during osteotomy and implant placement. *Int J oral Maxillofac Implants.* 2007; Mar-Apr; 22(2):208-12.
16. Loubele M, Guerrero ME, Jacobs R, Suetens P, Van Steenberghe D. A comparison of jaw dimensional and quality assessments of bone characteristics with Cone-Beam CT, spiral tomography, and multi-slice spiral CT. *Int J Oral Maxillofac Implants.* 2007; May-Jun; 22(3):446-54.
17. Turkyilmaz I, Tumer C, Ozbek EN, Tözüm TF. Relations between the bone density values from computerized tomography, and implant stability parameters: a clinical study of 230 regular platform implants. *J Clin Periodontol.* 2007; Aug; 34(8):716-22.

## Corresponding author:

Daniela Miranda Richarte de Andrade Salgado  
Universidade de São Paulo – Faculdade de Odontologia  
Av. Professor Lineu Prestes, 2227 – Cidade Universitária  
São Paulo-SP, CEP 05508-000  
Brazil

E-mail: daniricharte@hotmail.com

Received November 28, 2015  
Accepted December 8, 2015