

# Dens invaginatus: a cone beam computed tomography case report

*Dens invaginatus: relato de um caso por tomografia computadorizada de feixe cônico*

Frederico Sampaio Neves<sup>1</sup>, Luana Costa Bastos<sup>1</sup>, Solange Maria de Almeida<sup>1</sup>, Frab Norberto Bóscolo<sup>1</sup>, Francisco Haiter-Neto<sup>1</sup>, Paulo Sérgio Flores Campos<sup>2</sup>

<sup>1</sup>Piracicaba Dental School, University of Campinas, São Paulo-SP, Brazil; <sup>2</sup>School of Dentistry, Federal University of Bahia, Salvador-BA, Brazil.

## Abstract

One of the most common dental anomalies is dens invaginatus. As the name indicates, it is an invagination of the coronary or root surface, bounded by enamel, which can be so profound as to simulate the appearance of a tooth inside another. Usually occurs in permanent maxillary lateral incisors, followed by maxillary central incisors, premolars, canines and less frequently molars. In this article we will describe the cone beam computed tomography features of a type III dens invaginatus.

**Descriptors:** Dens in dente; Cone-beam computed tomography; Tooth abnormalities

## Resumo

Uma das anomalias dentárias mais comuns é o dens invaginatus. Assim como o nome indica, é uma invaginação da superfície coronária ou radicular, delimitada por esmalte, que pode ser tão profunda a ponto de simular a aparência de um dente dentro do outro. Normalmente ocorre em incisivos laterais superiores permanentes, incisivos centrais superiores, pré-molares, caninos e, menos frequentemente, molares. Neste artigo será descrito os achados por tomografia computadorizada de feixe cônico de um dens invaginatus tipo III.

**Descritores:** Dens in dente; Tomografia computadorizada de feixe cônico; Anormalidades dentárias

## Introduction

The dens invaginatus (DI) is a developmental anomaly resulting from a deepening or invagination of the enamel organ into the interdental papilla prior to the calcification of dental tissues<sup>1</sup>. The DI etiology is still unclear and controversial and several theories have been suggested, including alterations in tissue pressure, trauma, infection, or local discrepancy in the cellular hyperplasia<sup>2</sup>.

Clinical cases conjugating DI and other dental anomalies, like short roots, microdontia, taurodontism, obliterate pulp chambers, gemination, supernumerary teeth and dentinogenesis imperfect, have been related<sup>3</sup>.

Although it usually occurs in permanent maxillary lateral and central incisors others teeth can be involved less frequently, such as premolars, canines and molars. The presence of double DI in the same tooth or in deciduous dentition is an extremely rare condition<sup>4-5</sup>.

In cases of DI, the clinical aspects of the crown may vary, ranging from the normal to the most unusual and different shapes, such as a greater buccolingual diameter, peg-shaped, barrel-shaped and conical, and talon cusp. The presence of a deep blind foramen may be the first clinical sign indicating the existence of a DI<sup>6</sup>. Radiographically, the enamel bounded invagination may be identified extending from the crown to a varying distance into the root. The defects may vary in size and shape, from a loop-like, pear-shaped or a slightly radiolucent structure to a severe form resembling a "tooth within a tooth" (also named dens-in-dent)<sup>7</sup>.

The aim of this manuscript is to report the cone beam computed tomography features of a type III dens invaginatus characteristic case in a maxillary lateral incisor and discuss the relevant features associated to this dental anomaly.

## Case report

A 24-year-old woman attended a private oral radiology clinic to undergo cone beam computed tomography (CBCT) exam due to the presence of pain in the left maxillary lateral incisor region.

The exam was performed with the Frankfort Horizontal Plane parallel to the Horizontal Plane and perpendicular to the Median Sagittal Plane, with the axial slices, increment between them and multiplanar reconstructions thickness of 0.076mm, field of view (FOV)

of 50 cm x 38 cm, and the following exposure factors: 70 kV, 10 mA, taking 10 seconds to be performed.

The panoramic reconstruction revealed a morphologic alteration in the radicular portion of the maxillary lateral incisor and the presence of a slight periapical radiolucent lesion without sclerotic margins (Figure 1). The axial slices showed partial filling of the pulp chamber and canal with filling material and a second canal, located palatally, but without filling (Figures 2a-2c). Coronal slices showed an increase of the pulp chamber and periapical lesion causing destruction of the buccal bony plate, but without expanding it (Figures 3a-3c), as it could be represented in the virtual three-dimensional reconstruction (Figure 4). Based on these features the diagnosis of type III DI was stated.

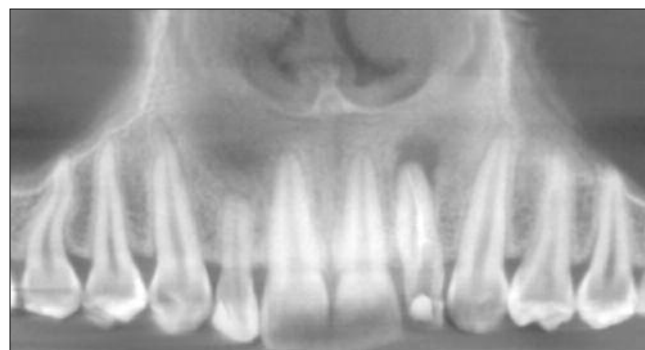

Figure 1. Panoramic reconstruction

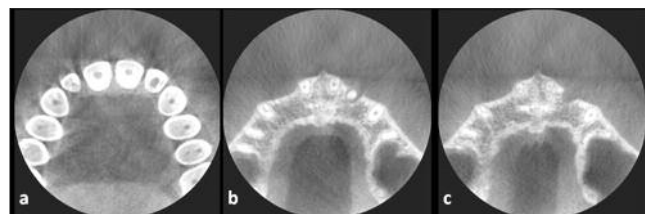
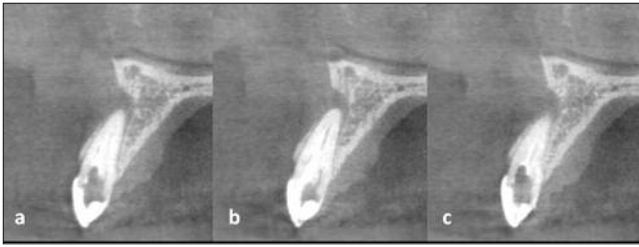
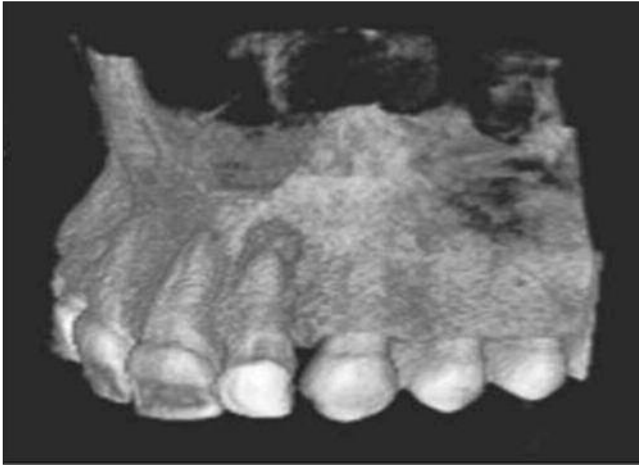

Figure 2. CBCT axial slices showing the existence of a second canal



**Figure 3. CBCT coronal slices showing the increased pulp chamber and periapical lesion**



**Figure 4. Virtual three-dimensional reconstruction in which the bony destruction could be seen**

## Discussion

Several authors have proposed to classify the radiographic and clinical presentations of DI, however, Oehlers<sup>8</sup> (1957) classification appears to be the most popular, due to its simple nomenclature and easy application. He categorized invaginations into three classes determined by how far they extend radiographically from the crown into the root:

- Type I: the invagination is minimal and enamel-lined; it is confined within the crown and does not extend beyond the level of the external amelo-cemental junction.
- Type II: the invagination is enamel-lined and extends into the pulp chamber but remains within the root canal with no communication with the periodontal ligament.
- Type III: the invagination extends through the root until the apical foramen and communicates with the periodontal ligament. Usually, there is no communication with the pulp.

In conventional radiographies is not always possible to determine, with high precision, the relationship between the invaginated portion of the tooth with the chamber and/or the root canals. In our patient case, the tomographic images make it possible to observe an invagination communicating with the periodontal space, resulting in a large periapical lesion, which permitted us to classify the condition as type III DI.

The incidence of type III DI is lower when compared to the other types, being the type II the most frequent<sup>9</sup>. In type III lesions, any infection beyond the invagination can lead to an inflammatory response through the periodontal tissues<sup>1</sup>, which could be observed in the present case.

DI does not have unusual clinical features in permanent tooth and probably is more common than other developmental anomalies. Uslu *et al.*<sup>10</sup> (2009) evaluated the development anomalies incidence in Turkish population (9000 patients), and the occurrence of DI was 5%. Hamasha and Alomari<sup>11</sup> (2004) evaluated the incidence in Jordanians and observed 0.65% of DI.

Clinically, several pulp (sensitivity to percussion and necrosis) and periodontal alterations (presence of periodontal pocket), as well as

dental mobility and presence of sinus track, can be associated with DI. Radiographically, one can observe an uncommon morphology of the crown and root, as well as the presence of periapical lesion<sup>1,12</sup>, increasing size of the pulp chamber and root canal ending in two apices<sup>13</sup>. In the present case, we could observe the periapical lesion but there is a single root apex corresponding to the final of the root canal and the apical extension of the dens invaginat.

Such cases always pose a diagnosis challenge to the clinician, as well as its treatment. Due to the intrinsic limitations of the conventional radiographies, they could not reveal the details of DI characteristics, like type and extension. In our case, the CT was fundamental to the final diagnosis.

The treatment for this dental anomaly varies in accordance with the tooth shape and the associated periapical and/or periodontal pathologies. In cases with severe shape alteration, and in which the periapical lesion is present, the endodontic treatment and re-anatomization of the tooth are the major therapeutic choice. When the conservative endodontic treatment fails, paraendodontic surgery and retrograde filling may be necessary<sup>12</sup>.

## Conclusion

In cases of DI, the image modality, mostly the CT, either multislice or cone beam, assume an extreme importance since it is possible to identify the severity degree of the anomaly.

## References

1. Bishop K, Alani A. Dens invaginatus. Part 1: classification, prevalence and aetiology. *Int Endod J.* 2008;41:1123-36.
2. Hülsmann M. Dens invaginatus: aetiology, classification, prevalence, diagnosis, and treatment considerations. *Int Endod J.* 1997;30:79-90.
3. Canger EM, Kayipmaz S, Çelenk P. Bilateral dens invaginatus in the mandibular premolar region. *Indian J Dent Res.* 2009;20:238-40.
4. Holan G. Dens invaginatus in a primary canine: a case report. *Int J Paediatr Dent.* 1998;8:61-4.
5. Zengin AZ, Sumer AP, Celenk P. Double dens invaginatus: report of the three cases. *Eur J Dent.* 2009;3:67-70.
6. Jung M. Endodontic treatment of dens invaginatus type III with three root canals and open apical foramen. *Int Endod J.* 2004;37:205-13.
7. John V. Non-surgical management of infected type III dens invaginatus with vital surrounding pulp using contemporary endodontic techniques. *Aust Endod J.* 2008;34:4-11.
8. Oehlers FA. Dens invaginatus (dilated composite odontome). I. Variations of the invagination process and associated anterior crown forms. *Oral Surg Oral Med Oral Pathol.* 1957;10:1204-18.
9. Ridell K, Mejäre J, Matsson L. Dens invaginatus: a retrospective study of prophylactic invagination treatment. *Int J Paediatr Dent.* 2001;11:92-7.
10. Uslu O, Akcam MO, Evirgen S, Cebeci I. Prevalence of dental anomalies in various malocclusions. *Am J Orthod Dentofacial Orthop.* 2009;135:328-35.
11. Hamasha AA, Alomari QD. Prevalence of dens invaginatus in Jordanian adults. *Int Endod J.* 2004;37:307-10.
12. Chaniotis AM, Tzanetakis GN, Kontakiotis EG, Tosios KI. Combined endodontic and surgical management of a mandibular lateral incisor with a rare type of dens invaginatus. *J Endod.* 2008;34:1255-60.
13. Demartis P, Dessi C, Cotti M, Cotti E. Endodontic treatment and hypotheses on an unusual case of dens invaginatus. *J Endod.* 2009;35:417-21.

### Corresponding author:

Frederico Sampaio Neves  
 Department of Oral and Maxillofacial Radiology  
 Piracicaba Dental School, University of Campinas  
 Av. Limeira, 901 - Areião  
 Piracicaba-SP, CEP 13414-018  
 Brazil

E-mail: fredsampaio@yahoo.com.br

Received April 4, 2010

Accepted May 28, 2010