

# Early oral rehabilitation of a child with amelogenesis imperfecta

## *Reabilitação oral precoce de uma criança com amelogênese imperfeita*

Natalino Lourenço Neto<sup>1</sup>, Marco A.B. Paschoal<sup>1</sup>, Tatiana Y. Kobayashi<sup>1</sup>, Daniela Rios<sup>1</sup>, Salete M.B. Silva<sup>1</sup>

<sup>1</sup>Bauru Dental School, University of São Paulo, São Paulo-SP, Brazil.

### Abstract

Amelogenesis imperfecta (AI) is an inherited disorder which results in enamel defects. The main clinical characteristics are extensive loss of tooth tissue, poor esthetics and tooth sensitivity. Early recognition followed by appropriate preventive care and oral rehabilitation is essential in the successful management of AI. This clinical report describes the management of a 3 year-old girl with a hypocalcified type of AI. The patient presented early extensive tissue loss of the superior incisors and molars, with general dentinal sensitivity. The first phase of the treatment was preventive measures to improve dental and periodontal health. On the second phase the anterior teeth were extracted and the molars were endodontic treated and covered with stainless steel crowns. A functional appliance was made to rehabilitate the anterior extracted teeth on the third phase. The performed treatment achieved satisfactory esthetic and function, which resulted in an improvement in the child's quality of life.

**Descriptors:** Amelogenesis imperfecta; Mouth rehabilitation; Esthetics, dental; Crowns; Space maintenance

### Resumo

Amelogênese imperfeita (AI) é uma doença hereditária que resulta em defeitos no esmalte. As principais características clínicas são a extensa perda de tecido dentário, estética prejudicada devido a coloração acastanhada dos dentes e sensibilidade dentária. O reconhecimento precoce seguido de cuidados preventivos adequados e reabilitação oral é essencial para o êxito nos tratamentos de AI. Este relato de caso clínico descreve o tratamento de uma criança de 3 anos com AI do tipo hipocalcificada. A paciente apresentava inicialmente extensas perdas de tecido nos incisivos superiores e molares, e uma sensibilidade dentinária generalizada. O tratamento reabilitador foi dividido em duas fases, na primeira fase do tratamento foram passadas à mãe e a criança medidas preventivas para melhorar a saúde dental e periodontal. Na segunda fase do tratamento os dentes anteriores foram extraídos e os molares foram tratados endodonticamente e cobertos com coroas de aço. Um aparelho funcional, visando manter o espaço dentário e oferecer uma estética de sorriso à paciente foi feito para reabilitar o arco anterior devido a extrações dentárias. O tratamento realizado foi satisfatório tanto na estética quanto na função, o que resultou em uma melhoria na qualidade de vida da criança.

**Descritores:** Amelogênese imperfeita; Reabilitação bucal; Estética dentária; Coroas dentárias; Mantenedor de espaço

### Introduction and Review of literature

Amelogenesis imperfecta (AI) is a group of inherited disorders characterized by abnormal enamel formation. These non-syndromic disorders are not associated with defects of other parts of the body or any other health problem<sup>1</sup>. These enamel defects are a result of gene mutations associated with amelogenin protein and enamelin protein, which are secreted during the amelogenesis process. However, most forms of AI do not have a defined molecular basis at this time<sup>2-3</sup>. AI follows an autosomal dominant, autosomal recessive or X-linked pattern of inheritance. The reported prevalence of AI is highly variable, it is reported to be 1:14.000 in the USA<sup>4</sup> and 1:700 in Europe<sup>5</sup>.

The enamel defects associated with AI are high variable, and the main clinical problems are extensive loss of tooth tissue, poor esthetics and tooth sensitivity. Enamel in both the primary and the permanent dentition will be affected<sup>6</sup>. Pulp and dentin are usually normal and the teeth are usually caries resistant<sup>7</sup>. Apart from enamel defects, AI has been also associated with inclusions, abnormalities in dental eruption, congenitally missing teeth, anterior open bite, pulpal calcifications, root and crown resorption, hypercementosis, root malformations and taurodontism<sup>8</sup>.

Several classifications of AI have been evolved over the years, based predominantly on the clinical and radiographic appearance of the enamel, however, a more recent classification also uses the mode of inheritance of the trait. So, these anomalies can be classified as hypocalcified, hypoplastic or hypomature based on radiographic findings, clinical and hereditary criteria<sup>9</sup>. The hypoplastic type accounts for 60-73% of cases and affects mainly females<sup>10</sup>. The enamel is usually thin but of normal hardness and there is a deficiency in the quantity of enamel that is properly mineralized<sup>11</sup>. The surface is usually smooth but with localized areas of thicker enamel

resulting in an abnormal crown contour. The enamel can also present normal thickness with pits or horizontal or vertical ridges<sup>12-13</sup>. The crowns appear to be hard and shiny and have normal to opaque white or yellow-brown color, but it is malformed.

The hypomature type affects 20-40% of cases and usually occurs in males<sup>7</sup>. AI involving hypomature is caused by a defect in final growth and maturation of enamel crystallites<sup>1</sup>. The thickness of the enamel is initially normal, however, it is lost soon after eruption because of its poor mineralization and reduced hardness. The enamel tends to chip from the underlying dentin rather than wear away<sup>3,7,12-13</sup>. Therefore, rough and highly sensitive dentin is exposed. Clinically the enamel presents a mottled appearance, opaque white to yellow-brown or red-brown coloration<sup>1,3,12-13</sup>.

Approximately 7% of individuals affected by amelogenesis imperfecta have the hypocalcified variant<sup>7</sup>. Hypocalcified AI is thought to result from a defect in initial crystallite formation followed by defective growth<sup>1</sup>. The enamel is also insufficiently mineralized, extremely soft and may show a chalky, dull color or a cheesy consistency with the possibility of a rapidly break down. These teeth have an abnormal shape when they erupt, an abnormal color and dull appearance. Loss of enamel from wear and staining tends to increase with age. Interestingly, the enamel at the cervical portion is frequently better calcified than that on the rest of the crown<sup>3,12</sup>.

The rough enamel surface, which is susceptible to extrinsic staining and abnormal shape of the crown, cause the major esthetic problem. In addition, the rough enamel surface, which usually extends subgingivally, predisposes to plaque retention and calculus formation. Therefore, the gingival health of many of these teeth is often compromised<sup>12</sup>.

An accurate diagnosis is important to exclude the presence of a systemic condition that exhibits generalized enamel hypoplasia as an accompanying feature; thus the appropriate genetic counseling can be scheduled. Additionally, by establishing the type of amelogenesis im-

perfecta, the most appropriate form of restorations can be prescribed for the affected teeth<sup>13</sup>.

Although the AI subtype and severity may limit potential treatment options, a recently published survey reported the importance of treating the AI patient not only from a functional standpoint, but also from a psychosocial health standpoint<sup>1,12</sup>. The impact, even on a child who has teeth affected by AI cannot be underestimated.

Treatment of AI depends on the individual diagnosis and phenotype, that is why numerous treatments have been described for the restoration of the esthetics and function of teeth in patients suffering from AI<sup>2-3,10</sup>. However there is few information in the literature regarding childhood oral rehabilitation of AI. This clinical report describes the early treatment in a child with hypocalcified type AI.

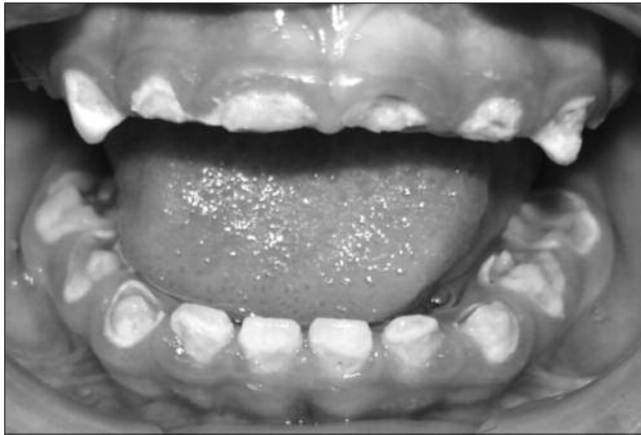

Figure 1. Initial appearance

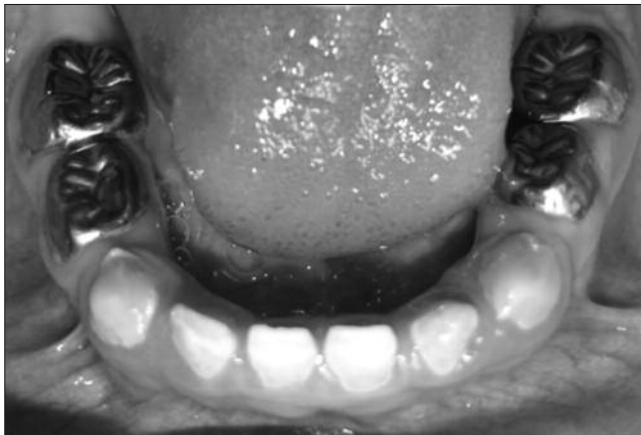


Figure 2. Stainless steel crowns placed on all mandibular molars

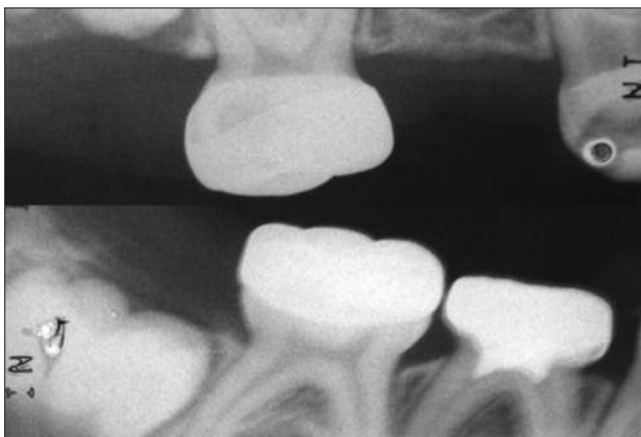


Figure 3. Bitewing radiograph of the right side

## Case report

The patient, a 3 year-old girl, was referred to the Pediatric Dentistry Clinic, Bauru Dental School, University of São Paulo for evaluation and treatment. Prior to treatment, detailed medical and dental history was obtained from the mother's child. The dental family history revealed that none of parents, brothers or relatives suffered from similar dental conditions. Intra-oral examination showed extensive tissue loss of the superior incisors and molars, a poor oral hygiene and a moderate chronic marginal gingivitis (Figure 1). All the primary teeth were partially covered by hypocalcified enamel. The molars were severely affected with loss of occlusal enamel layer, resulting in a reduction of the occlusal vertical dimension. Enamel defects were present however, the exposed dentin seemed normal. The dental family history, clinical and radiographic features were consistent with a possible diagnosis of autosomal recessive hypocalcified amelogenesis imperfecta.

The exposed dentin was hypersensitive, which unable the patient to properly chew the food and to brush the teeth. In addition, the social history revealed that the young patient and her parents were upset with her oral appearance.

In order to restore the mastigatory function, reduce the reported tooth sensitivity, improve the esthetics and prevent further loss of tooth structure, the treatment was conduct in three phases.

The first phase of the treatment started with preventive measures to improve dental and periodontal health and to modify the child's attitude and behavior towards dental treatment. The measures included diet analysis and advice, extensive oral hygiene instruction, professional dental plaque remove and topical fluoride application.

On the second phase, the maxillary incisors and first molars were extracted due to the extensive dental tissues loss, which contra indicated restoration. Following the treatment sequence, maxillary second molars and all of the mandibular molars and canines were temporarily restored with resin modified glass ionomer cement (Vitremer

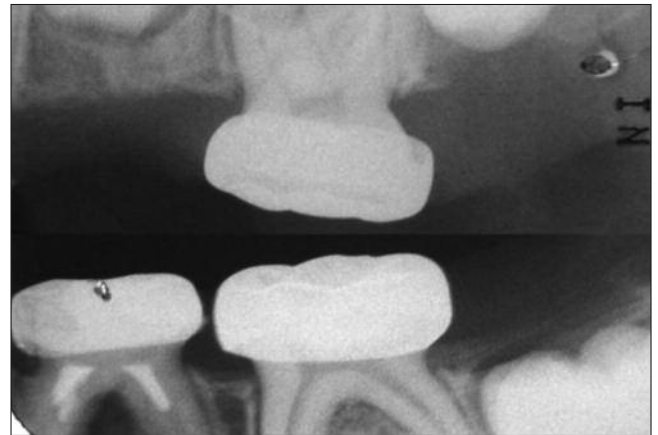

Figure 4. Bitewing radiograph of the left side

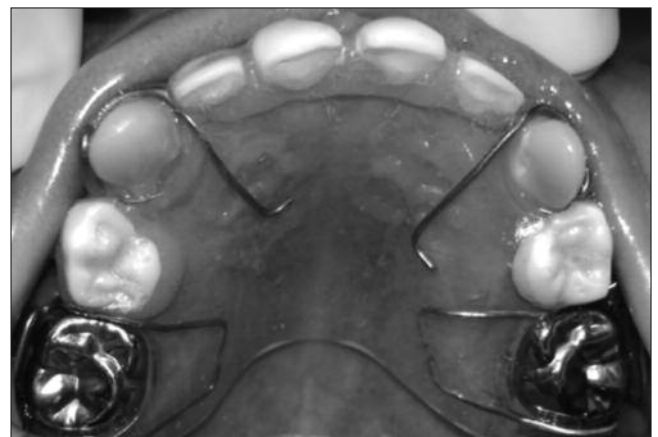


Figure 5. Functional maintenance in the maxilla

3M/ESPE St Paul, MN, USA) aiming to alleviate the teeth sensitivity. This procedure was done under cotton rolls isolation. Even in the second phase of the treatment due to severe loss of tissue when the removal of the affected tissue it was necessary to do the endodontic treatment in two mandibular first molars, to the subsequent indication of the stainless steel crowns. The molar from the right side received a pulpotomy using MTA (Angelus Indústria de Produtos Odontológicos Paraná, PR, Brazil), and the molar from the left side received a root canal treatment using a paste of calcium hydroxide to filling the canals.

Considering the loss of dental tissues of the posterior teeth, it was necessary to indicate stainless steel crowns (3M/ESPE) to restore occlusion and the occlusal vertical dimension of the child. The preformed stainless steel crowns were placed on the maxillary second molars following minimal slice preparation of the teeth. At the subsequent visit, stainless steel crowns were placed on the mandibular molars (Figure 2). All of them were cemented with resin modified glass ionomer cement for cementation (Rely-X, 3M/ESPE St Paul, MN, USA). The adaptation and quality of the margins of the stainless steel crowns were evaluated using bitewing radiographs (Figures 3 and 4). The maxillary canines were restored with a micro-fill resin composite, Filtek Z250 (A2 shade, 3M/ESPE), using preformed acetate crowns (TDV Dental Ltda, Pomerode, SC, Brazil).

To improve esthetic and to reestablish maxillary anterior function, a removable appliance was made to rehabilitate the superior anterior region, on the third phase (Figure 5).

## Discussion

Amelogenesis imperfecta has marked psychosocial effects, which suggests that dental treatment could be medically necessary<sup>1</sup>, it's very important to have teeth and oral esthetics for a normal psychosocial development. However, the restoration of esthetics and function of teeth in childhood patients suffering from amelogenesis imperfecta often represents to the dentist a major challenge<sup>14</sup>.

Attention should first be given to the patient's level of oral hygiene and dietary habits, which can compromise the rehabilitation procedures. Poor oral hygiene is a recognized problem in patients with AI, because of the rough enamel surface which causes plaque retention and to the sensitivity experienced when brushing<sup>6</sup>. Therefore, oral hygiene instructions are essential and corresponded to the first phase of the presented treatment<sup>15</sup>.

Historically, patients with severe AI have been treated with multiple extractions of the primary teeth followed by the construction of complete dentures<sup>8</sup>. Nowadays, there is a range of materials used to restore the teeth that includes the use of composite resin, polycarbonate crowns, stainless steel crowns (SSCs), glass ionomer cement and functional maintenance dispositives to restore a mutilated dentition<sup>15</sup>. In most cases, full coverage is desirable for posterior primary teeth due to the extensive loss of enamel and also to prevent further loss of tooth structure<sup>16</sup>. In children with the primary and the early mixed dentition, SSCs are the most effective type of restoration<sup>15-16</sup>.

The SSCs are extremely durable, relatively cheap, subject to minimal technique sensitivity during placement, and offers the advantage of full coronal coverage<sup>17</sup>. In primary teeth, the SSCs find application following pulpotomy/pulpectomy and is also applicable for teeth with developmental defects, large carious lesions involving multiple surfaces where amalgam is likely to fail and fracture teeth<sup>17</sup>.

The successful management of AI during childhood requires the cooperation and motivation of the patient and parents. In the present case, the AI was identified in a three-year-old girl with a full primary dentition. The objective during the second phase of the treatment was to alleviate the dental sensitivity of the patient, which was achieved by placing glass ionomer cement on all of the four mandibular molars, canines and maxillary second molars. According to the mother, after the restorative procedures, the patient's dental hypersensitivity disappeared completely and the chewing function increased. It became evident that this was a strong motivation to improve her behavior and the level of cooperation during treatment.

Finally, the third phase of the treatment involved the reestablis-

hment of the esthetic and function of the anterior region, with a space maintainer, looking toward the psychosocial aspect of the child.

Frequent recalls to control the space maintainer adaptation, the oral hygiene and the dietary habits are strongly recommended to preserve the maxillary development, to prevent caries and to improve longevity to restorative/rehabilitation procedures<sup>15</sup>. In addition at the eruption of the permanent dentition, beginning at six years of age, the professional should provide special attention for AI patients to guarantee early restorative minimally invasive intervention.

## Conclusion

The psychosocial effects of AI on affected individuals, even in children are significant<sup>5</sup>. Although more simple, the treatment during the primary dentition must be performed with attention, in order to reestablish both the function and the patient/parents expectations and to prevent serious problems in the future occlusion and social adaptation of the patient.

## References

1. Coffield KD, Phillips C, Brady M, Roberts MW, Strauss RP, Wright JT. The psychosocial impact of developmental dental defects in people with hereditary amelogenesis imperfecta. *J Am Dent Assoc.* 2005;136:620-30.
2. Ozturk N, Sari Z, Ozturk B. An interdisciplinary approach for restoring function and esthetics in a patient with amelogenesis imperfecta and malocclusion: a clinical report. *J Prosthet Dent.* 2004;92:112-5.
3. Türkün LS. Conservative restoration with resin composites of a case of amelogenesis imperfecta. *Int Dent J.* 2005;55:38-41.
4. Witkop CJ, Sauk JJ. Heritable defects of enamel. In: Stewart R, Prescott G, editors. *Oral facial genetics.* St Louis: Mosby; 1976. p.151-226.
5. Bäckman B, Holm AK. Amelogenesis imperfect: prevalence and incidence in northern Swedish country. *Community Dent Oral Epidemiol.* 1986;14:43-7.
6. Visram S, McKaig S. Amelogenesis imperfecta – clinical presentation and management: a case report. *Dent Update.* 2006;33:612-4, 616.
7. Bsoul SA, Flint DJ, Terezhalmay GT, Moore WS. Amelogenesis imperfecta. *Quintessence Int.* 2004;35:338-9.
8. Toksavul S, Ulusoy M, Türkün M, Kümbüloğlu O. Amelogenesis imperfecta: the multidisciplinary approach. A case report. *Quintessence Int.* 2004;35:11-4.
9. Witkop CJ Jr. Amelogenesis imperfect, dentinogenesis imperfect and dentin dysplasia revisited: problems in classification. *J Oral Pathol.* 1988;17:547-53.
10. Crawford PJ, Aldred M, Bloch-Zupan A. Amelogenesis imperfecta. *Orphanet J Rare Dis.* 2007;4:2-17.
11. Kwok-Tung L, King NM. The restorative management of amelogenesis imperfecta in the mixed dentition. *J Clin Pediatr Dent.* 2006;31:130-5.
12. Akin H, Tasveren S, Yeler DY. Interdisciplinary approach to treating a patient with amelogenesis imperfecta: a clinical report. *J Esthet Restorative Dent.* 2007;19:131-5.
13. Nel JC, Pretorius JA, Weber A, Marais JT. Restoring function and esthetics in a patient with amelogenesis imperfecta. *Int J Periodontics Restorative Dent.* 1997;17:478-83.
14. Seow KW. Clinical diagnosis and management strategies of amelogenesis imperfecta variants. *Pediatr Dent.* 1993;15:384-93.
15. Bouvier D, Duprez JP, Bois D. Rehabilitation of young patients with amelogenesis imperfect: a report of two cases. *ASDC J Dent Child.* 1996;63:443-7.
16. Randall RC. Literature review for AAPD: preformed metal crowns for primary and permanent molar teeth. Consensus Conference on Pediatric Restorative Dentistry. San Antonio, Texas, Apr 15-16; 2002.
17. Seale NS. The use of stainless steel crowns. *Pediatr Dent.* 2002;4:501-5.

Corresponding author:

Natalino Lourenço Neto  
Bauru School of Dentistry, University of São Paulo  
Al. Dr. Octávio Pinheiro Brisolla, 9-75  
Bauru-SP, CEP 17012-901  
Brazil

E-mail: natalusp@yahoo.com.br

Received May 6, 2010

Accepted June 25, 2010